

Peer Review, Related Issues and Findings that Might Cause Differences between Original and Reviewing Pathologists

**Klaus Weber, PhD, DVM, MS Biol, DJSTP
AnaPath GmbH, Switzerland**

with contribution of Dr. J.F.Hardisty, EPL Inc.

Any Section is an artifact because.....

- **3-4 um in thickness.**
- **One moment in agonal stage of cells.**
- **Shrinking is always there.**
- **Some structures are stained, others not.**
- **Covered.**
- **Can we still do something wrong?**
- **We can: tresholds, opinion, recognition, substraction of artifacts.....!**

But there is something what we should use.....

‘...Can Pathology rise to the challenges inherent in the new world of One Medicine? For over a century and a half of modern pathology, we have possessed a unique technology, the microscope. We possess a unique skill, microscopic interpretation...’

Cardiff RD, Ward JM, Barthold SW (2008): ‘One medicine - one pathology’: are veterinary and human pathology prepared? Laboratory Investigation, 88: 18–26

And High Qualified Technicians, and discussion, discussion, discussion.....!

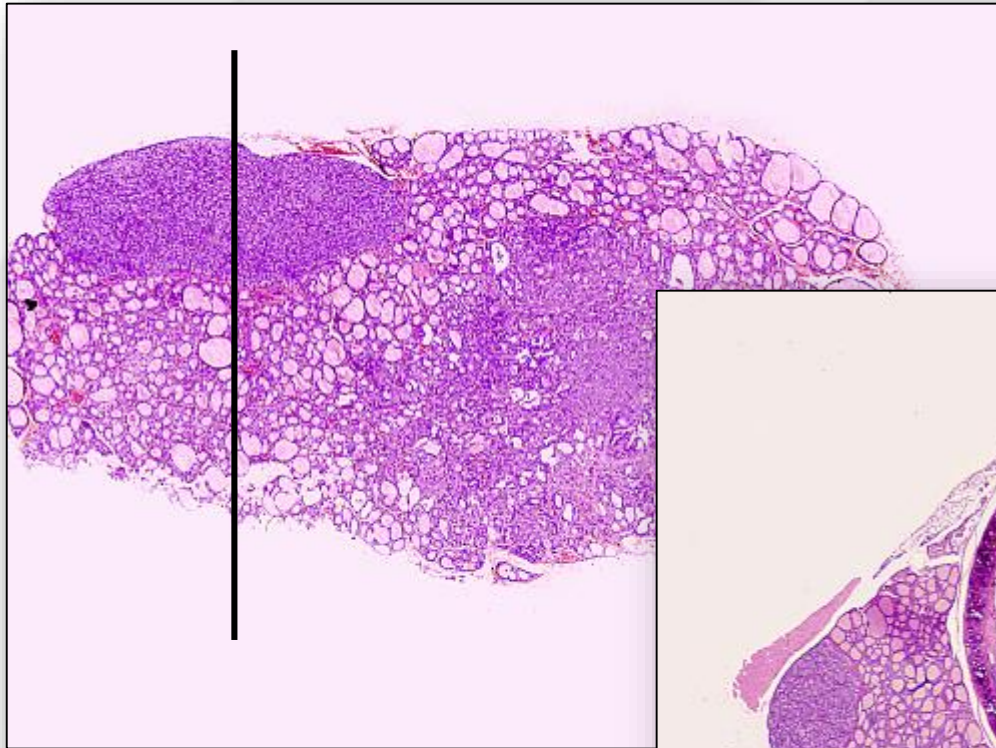
What can we do wrong?

Sampling procedures may be insufficient:

- little tissue
- wrong trimming procedures

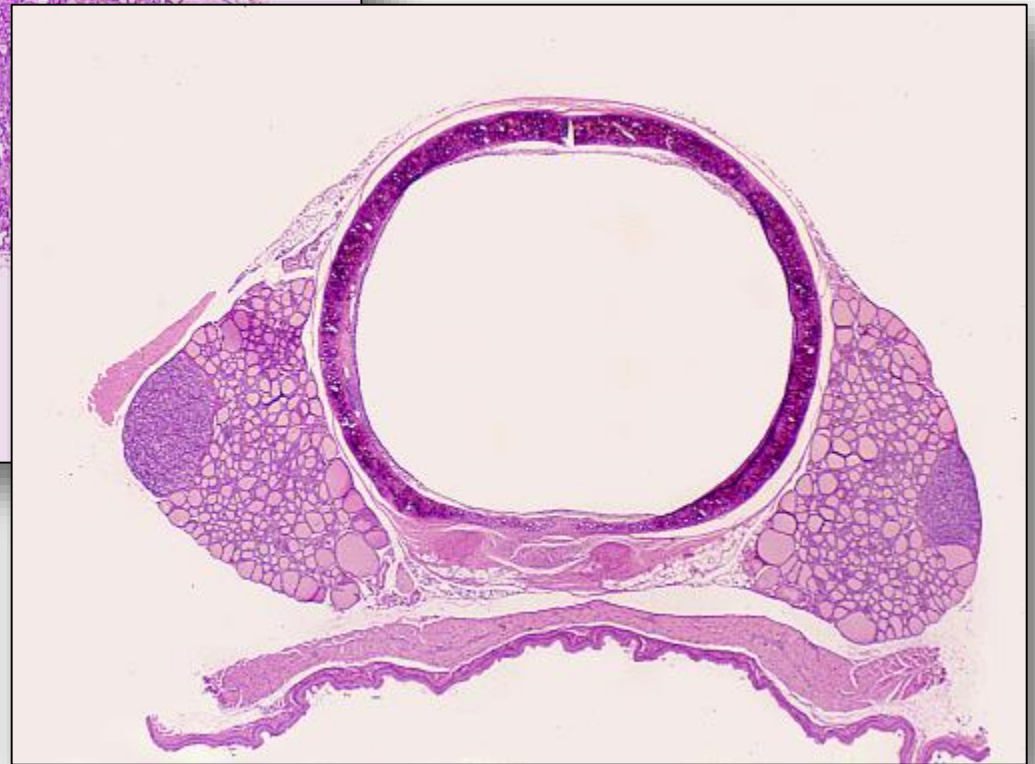AnaPath

Artifacts induced during tissue trimming



Longitudinal

Transversal

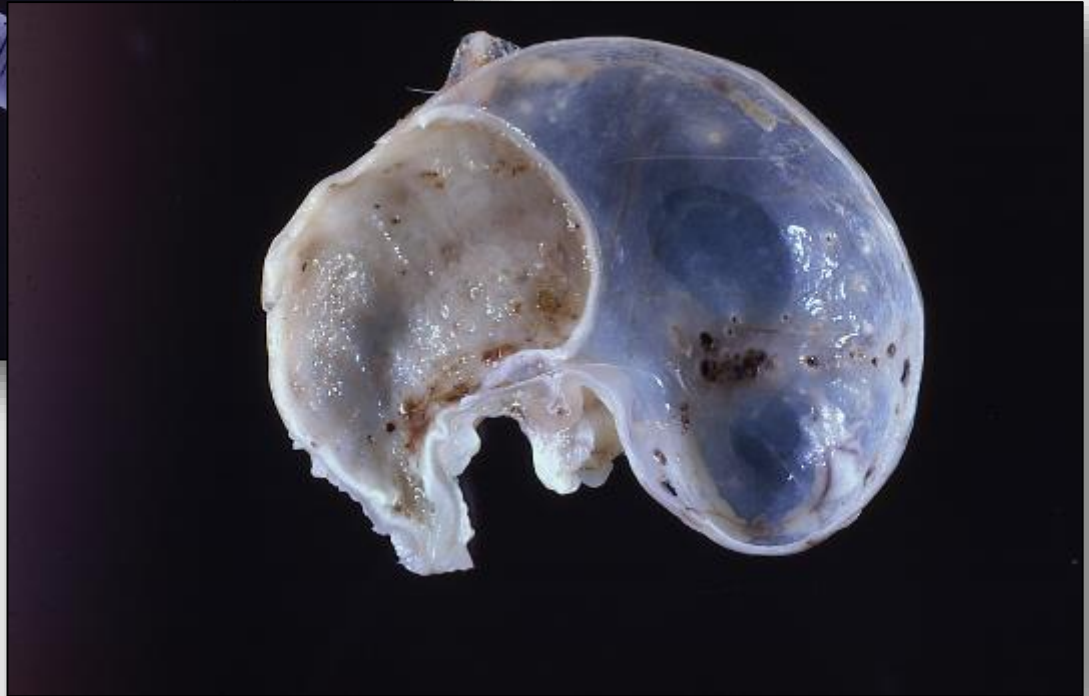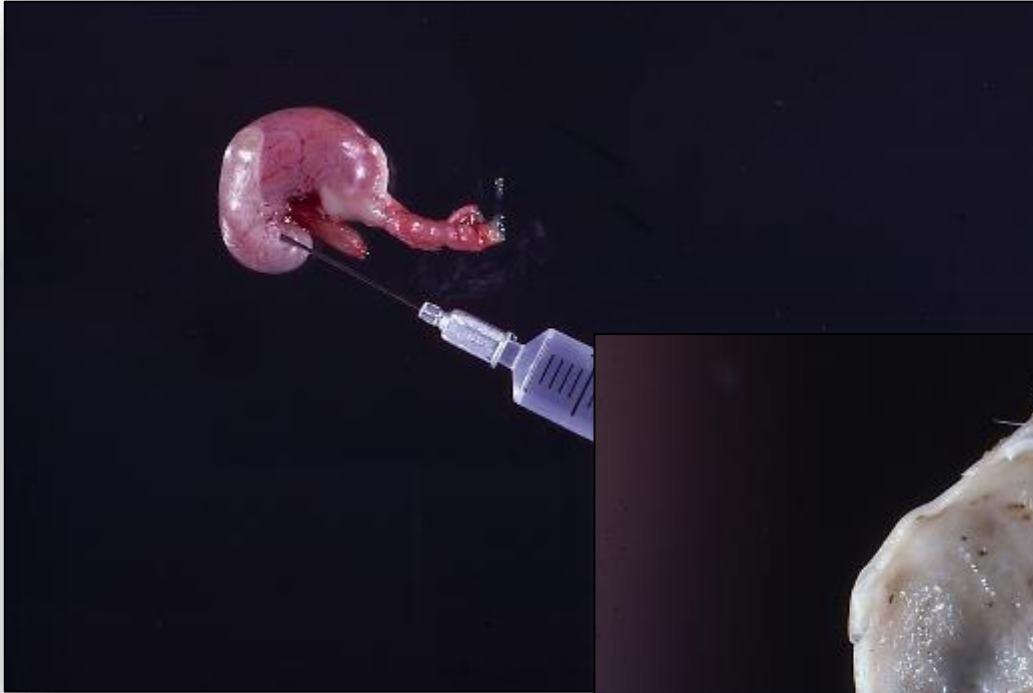


What can we do wrong?

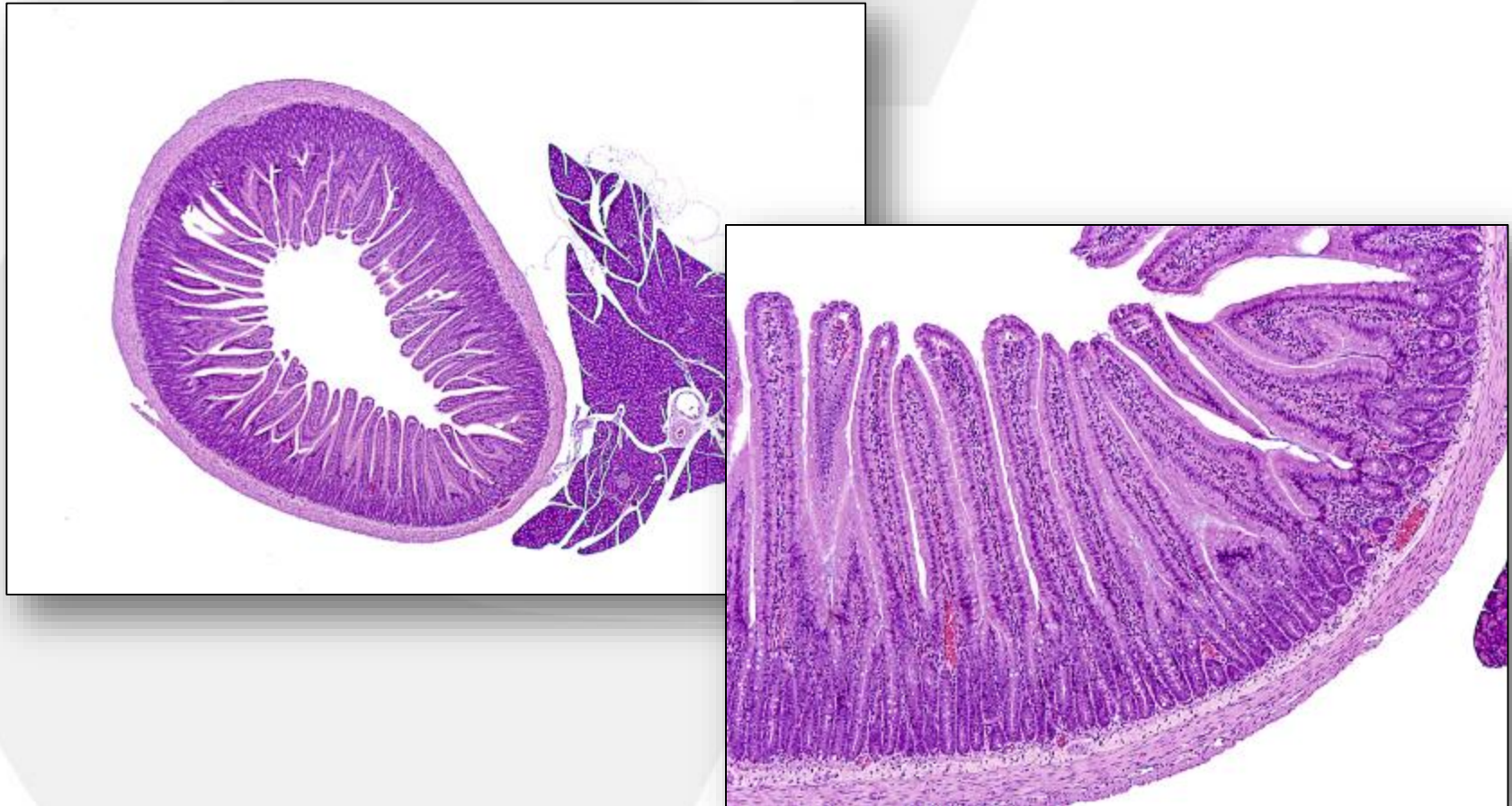
how to avoid the enhancement or unnecessary tissue artifacts

- **pressure**
- **inadequate fixatives**
- **misinterpretation**

Tissue Artifacts Induced by Fixation Pressure

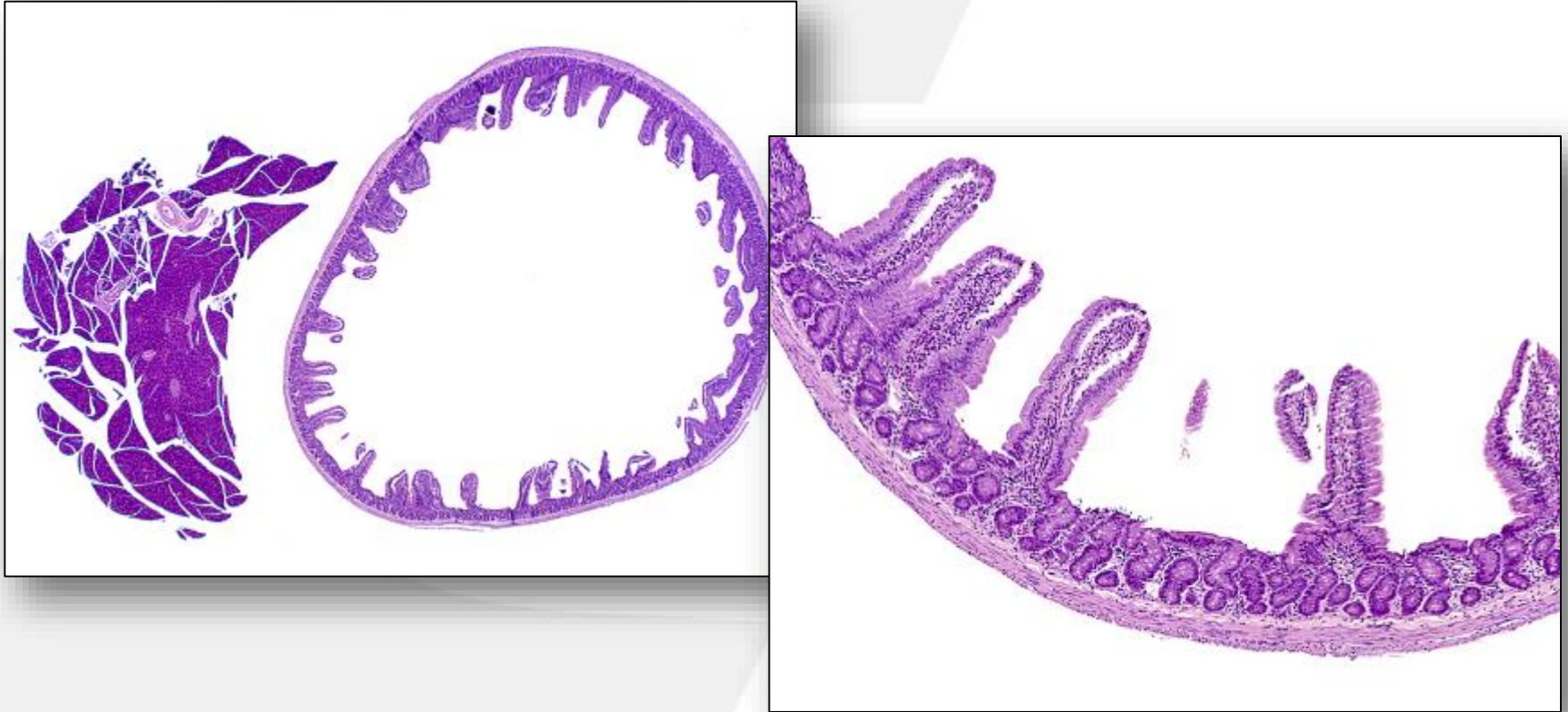


Tissue Artifacts Induced by Fixation



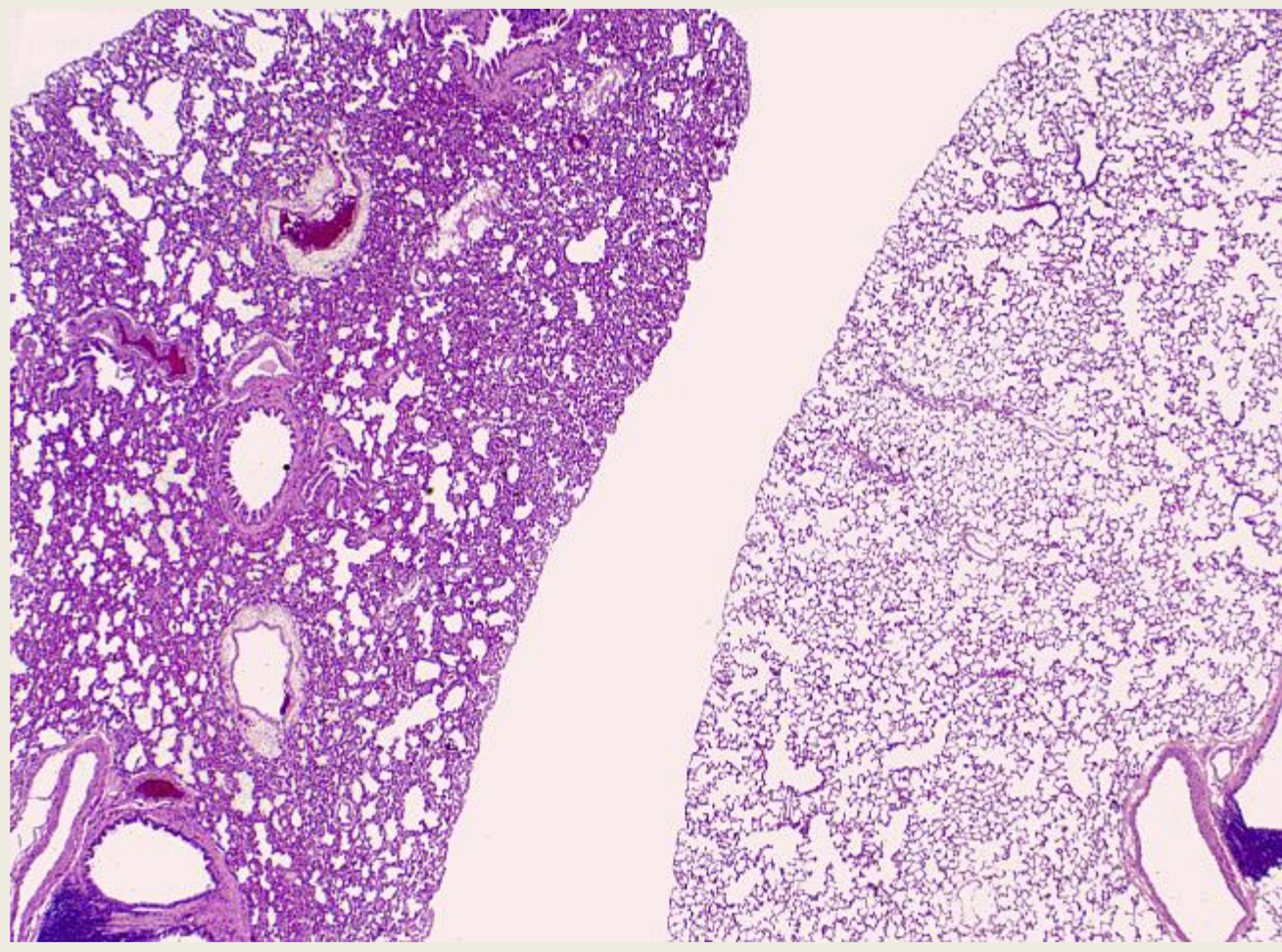
Normal Duodenum and Pancreas. Properly Inflated with Formalin at Necropsy.

Tissue Artifacts Induced by Fixation Pressure



Normal duodenum and pancreas overinflated with formalin at necropsy

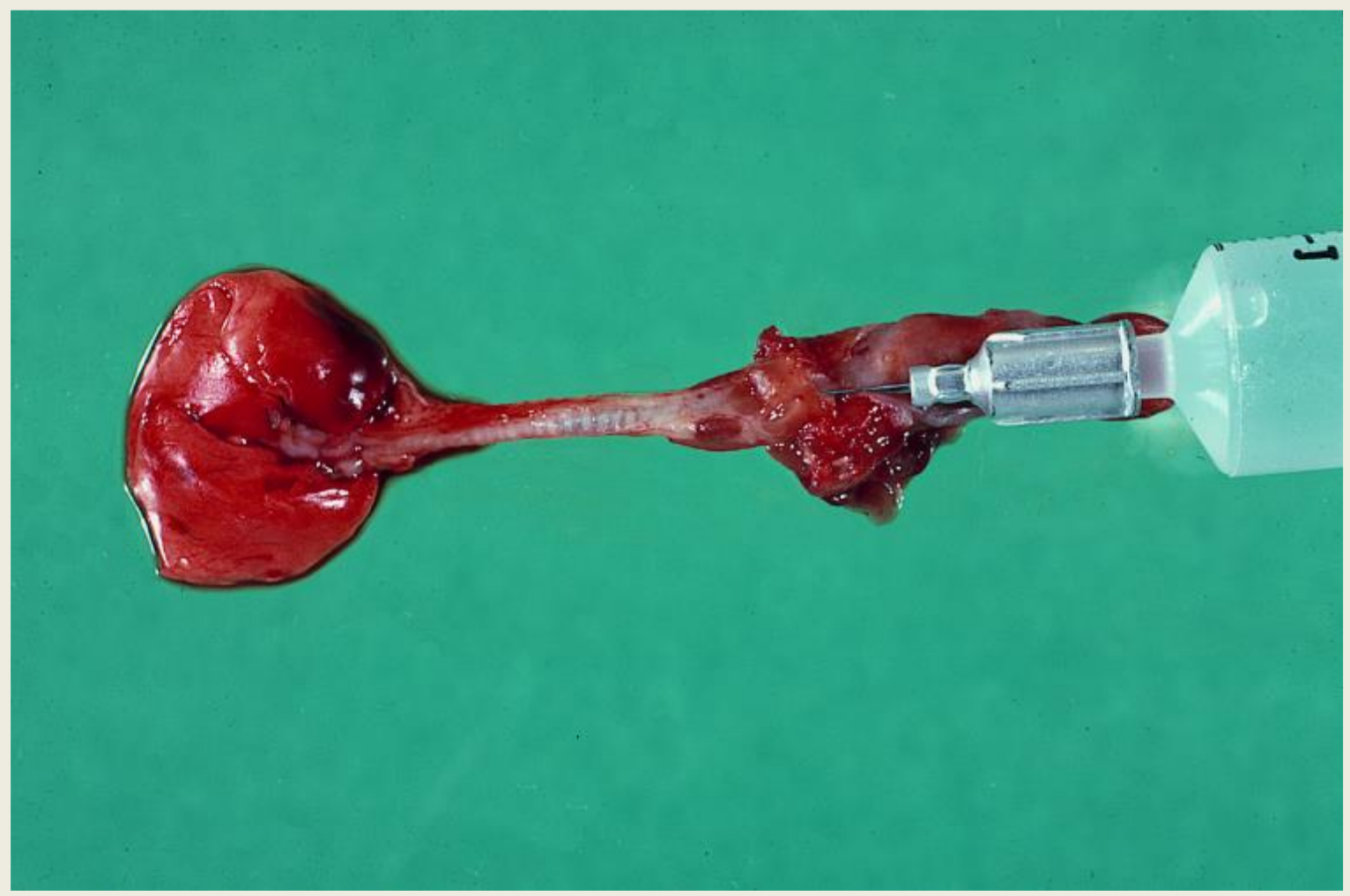Pulmonary Infusion: Why? Influence on Diagnose!



Noninflated lung

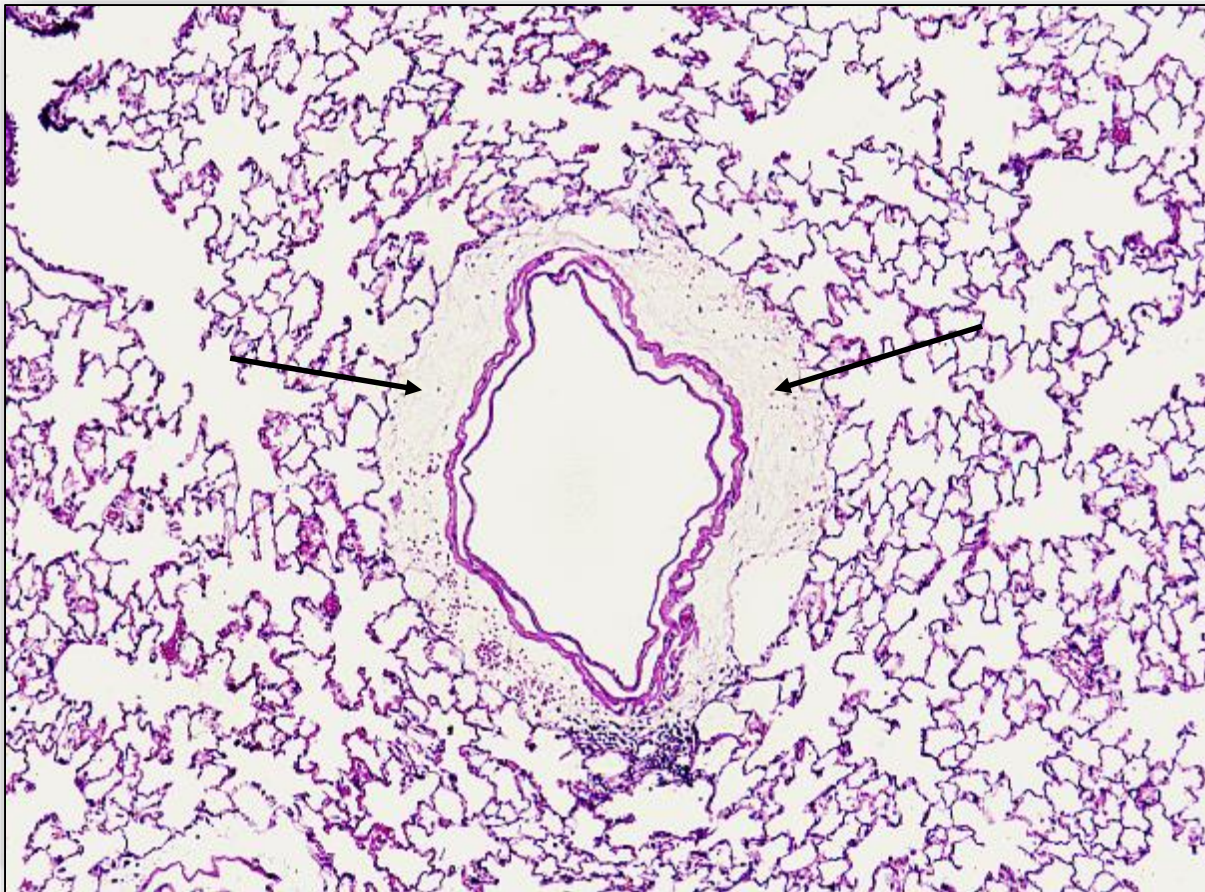
Inflated lung

Pulmonary infusion (mouse)



Pulmonary Infusion may cause artifacts

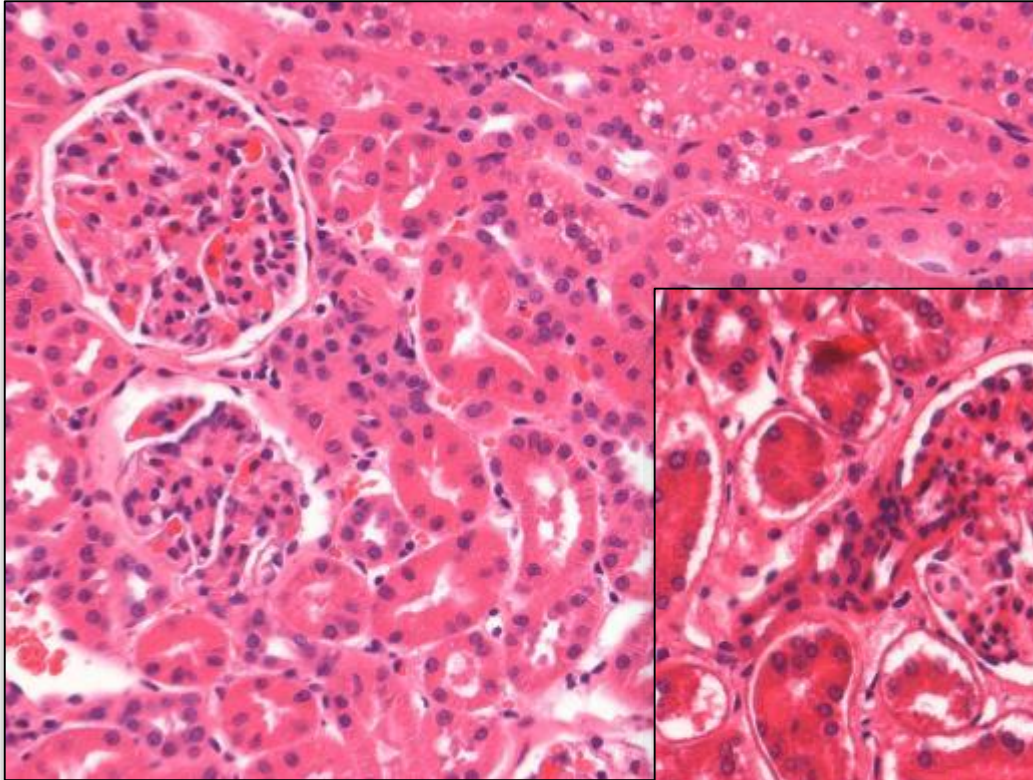
Separation of the perivascular interstitial tissue sometimes confused with perivascular edema



Inappropriate fixative may cause inadequate diagnose

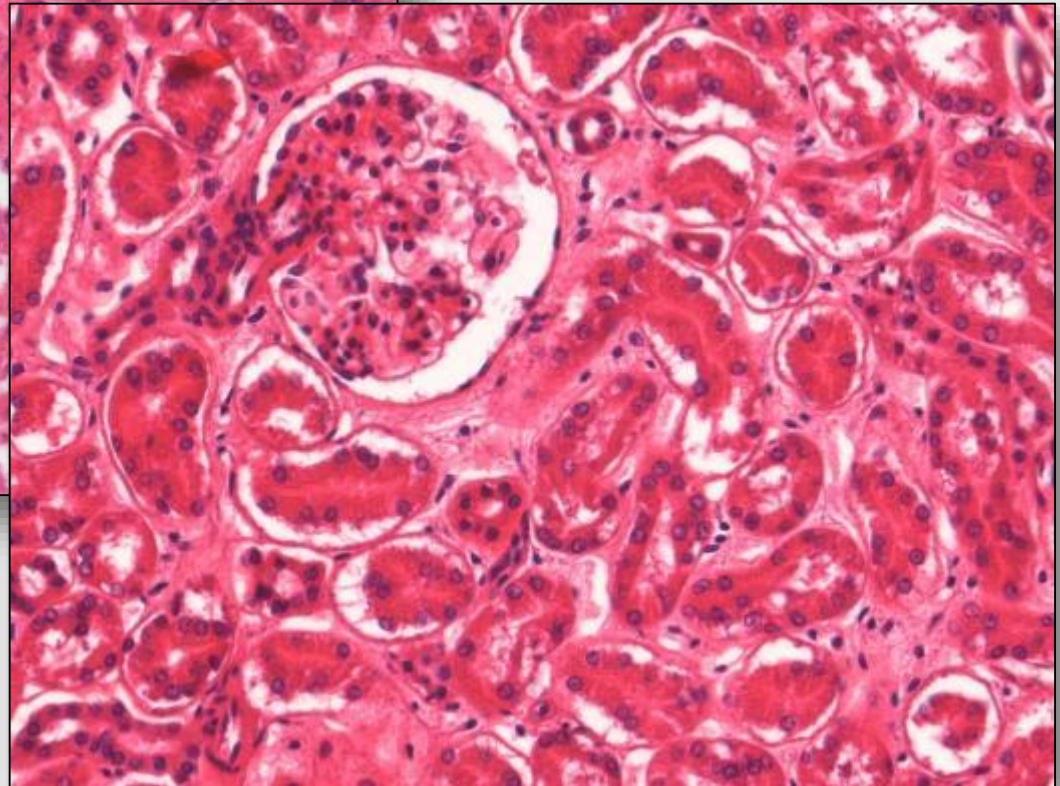
- **Study on induced artifacts performed at Harlan incl.**
- **use of different fixatives, fixation time, drying out of organs, cooling, freezing, autolysis etc.**
- **Inappropriate fixatives may cause alterations confused with induced lesions e.g. degeneration, necrosis etc.**

Artifacts by Fixation: Formaldehyde vs Ethanol

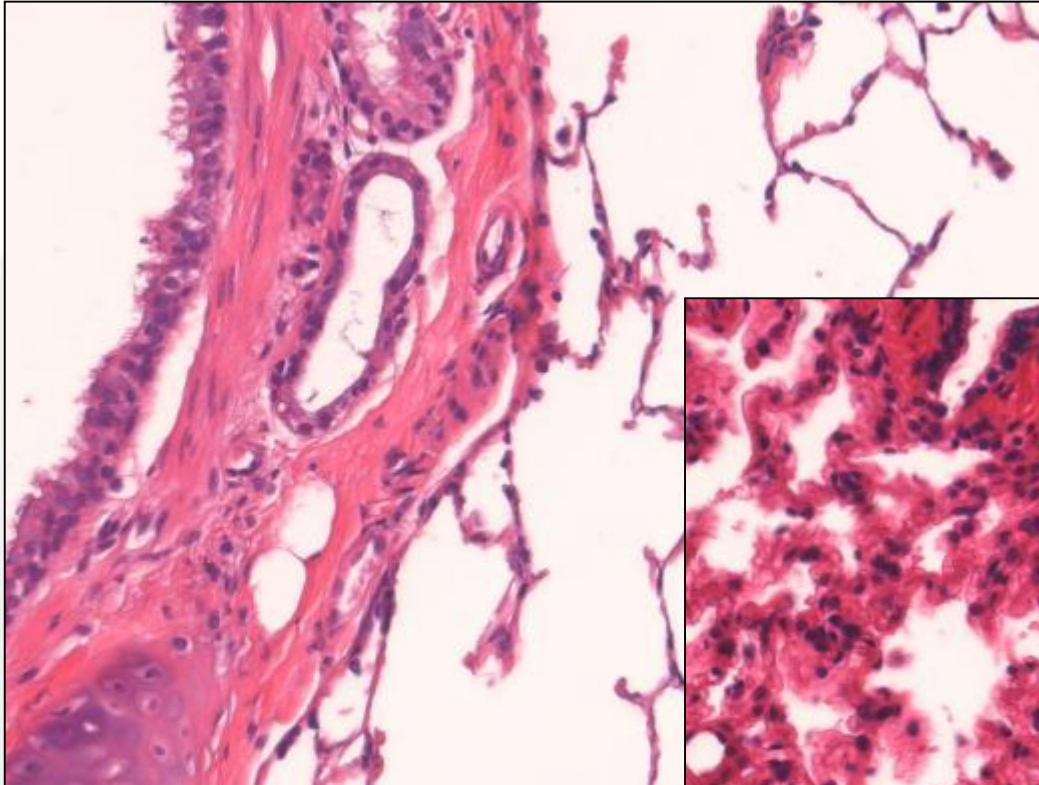


**Kidney: block 5x5
mm, F4%,1 day
Dog.**

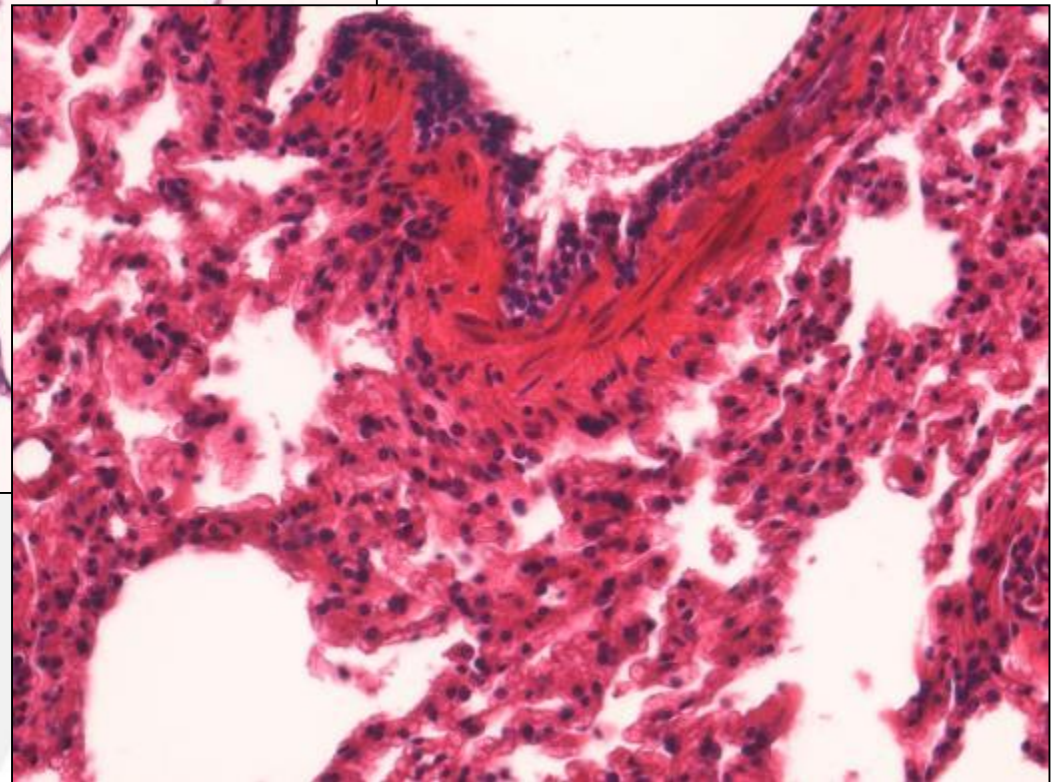
**Kidney: block 5x5
mm, ET70%,1 day
Dog.**



Artifacts by Fixation: Formaldehyde vs Ethanol

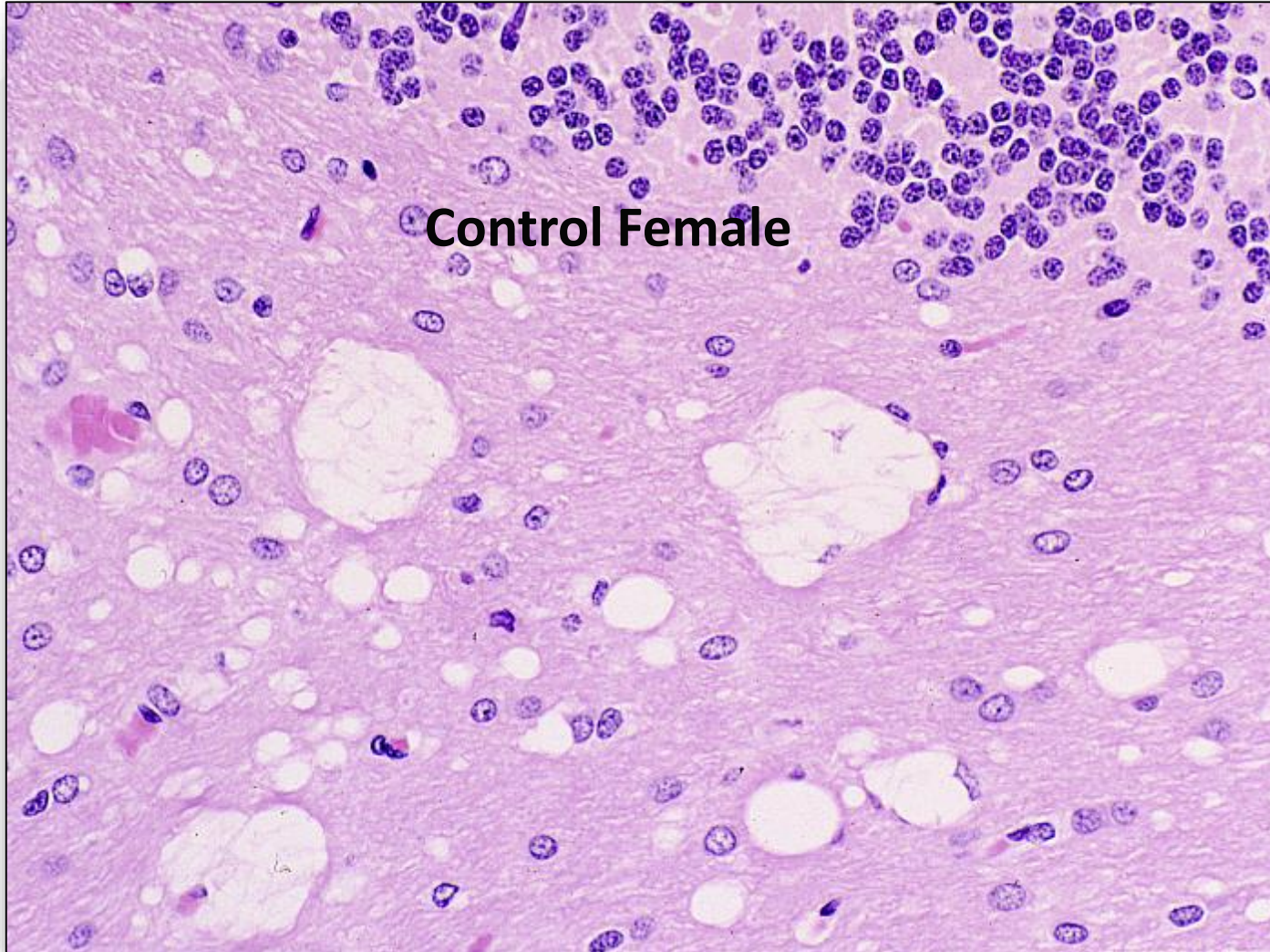


**Lung: block 5x5 mm,
ET70%,1 day
Dog.**

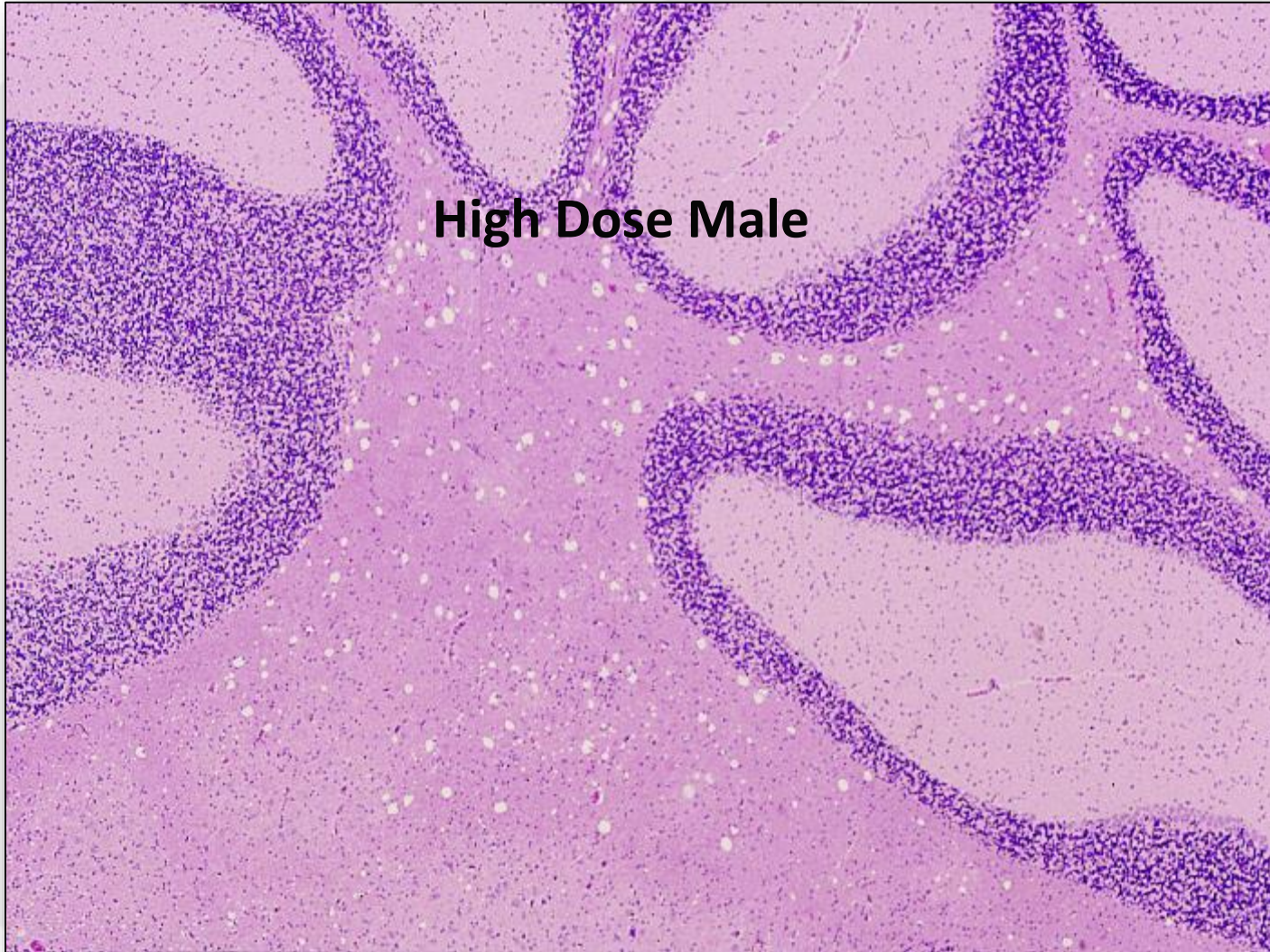

**Lung: block 5x5 mm,
F4%,1 day
Dog.**

Cytoplasmic vacuolation in neural tissue produced by ethanol fixatives



Cytoplasmic vacuolation in neural tissue produced by ethanole fixatives



Cytoplasmic vacuolation in neural tissue produced by ethanol fixatives

Control Males

High Dose Males

Control Females

High Dose Females

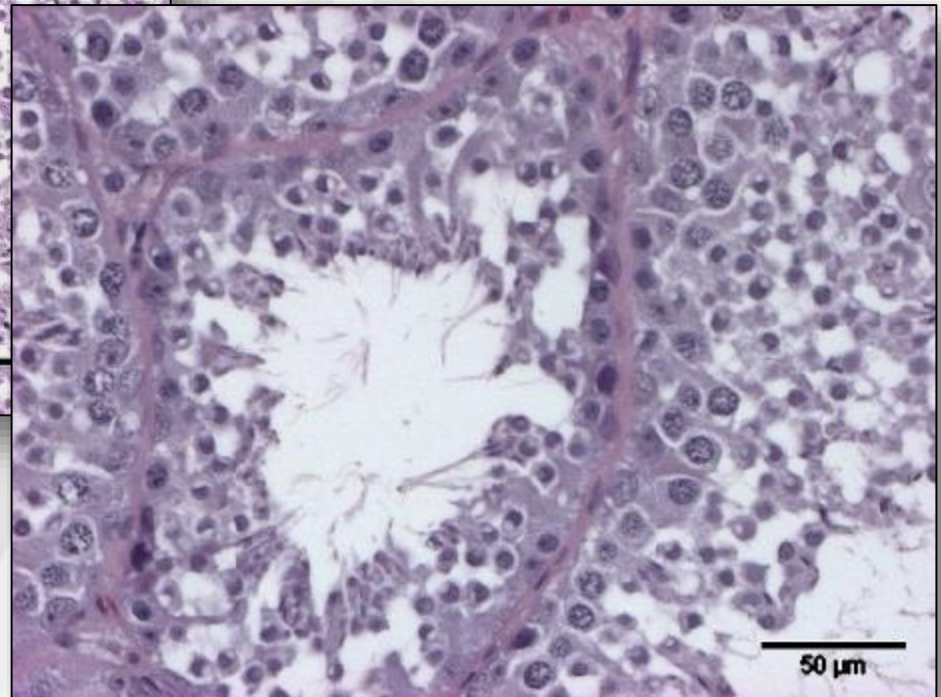
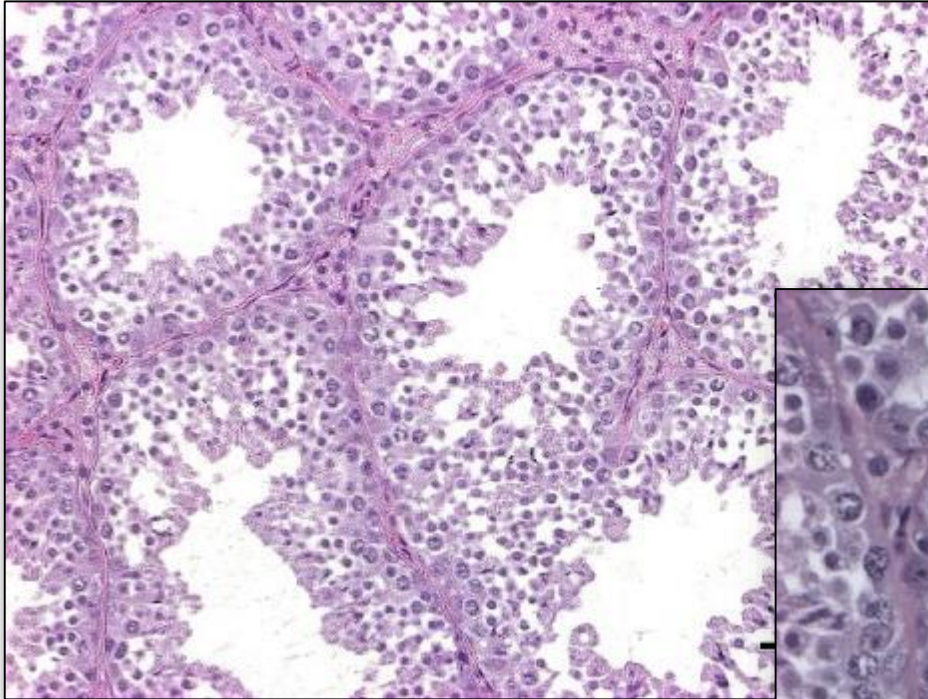
Trimmed on Thursday

Trimmed on Friday

Trimmed on Friday

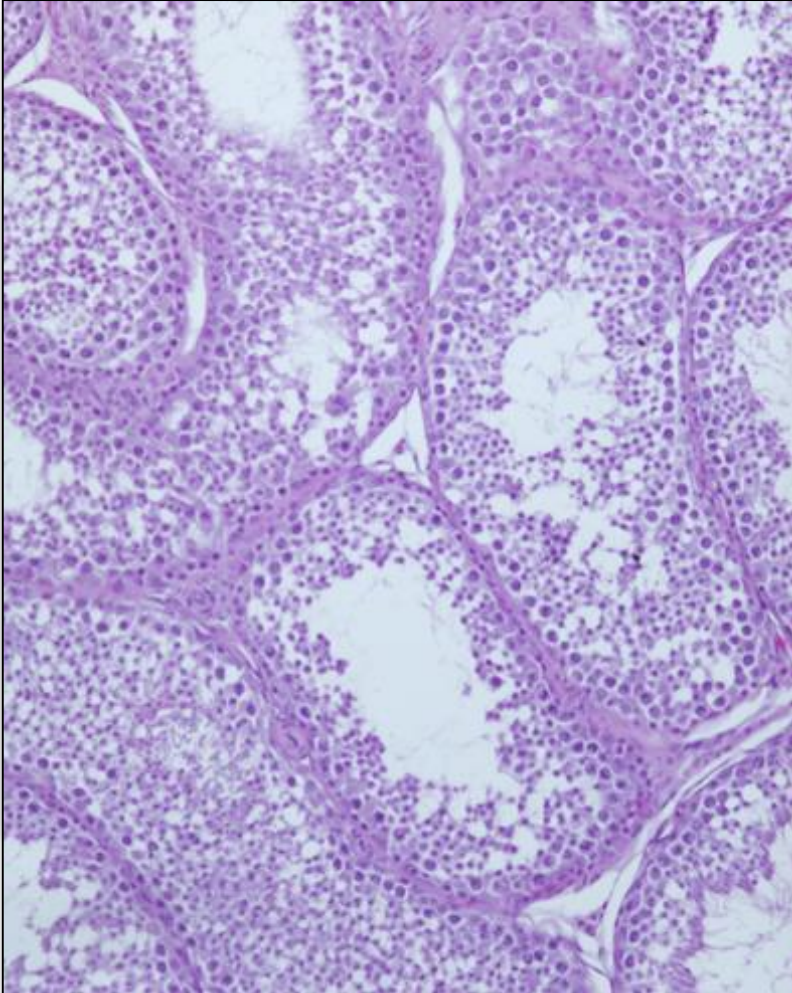
Trimmed on Monday

Artifacts vs testicular lesions with formalin

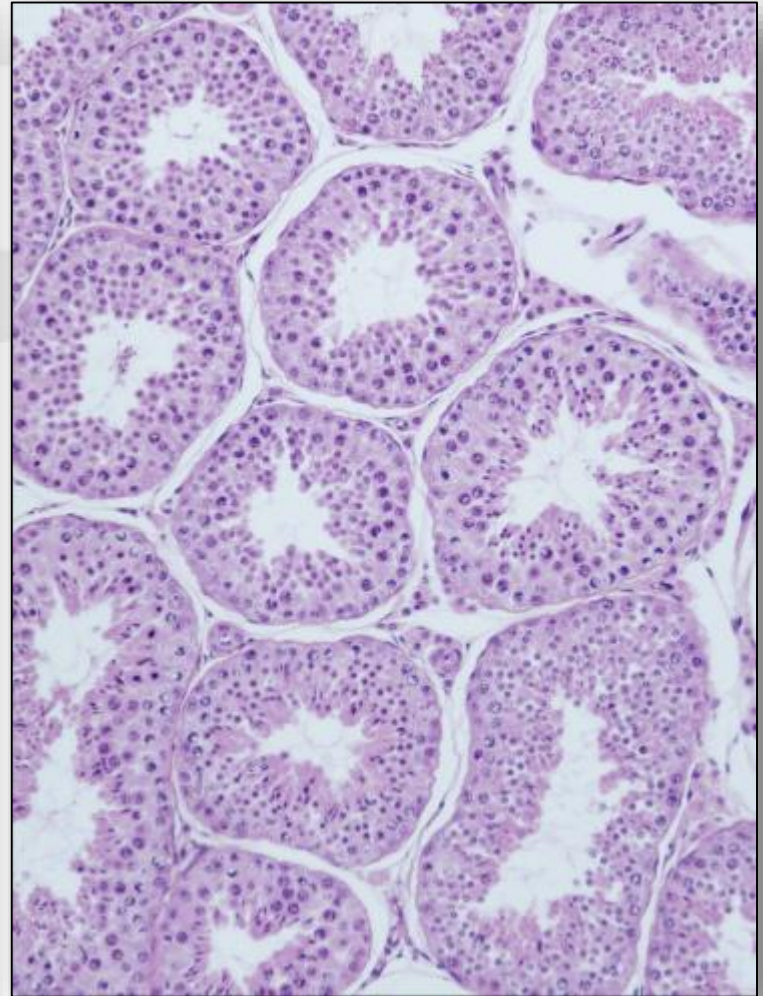


Fixation artifacts involving the testes (control dogs)

Formaldehyde

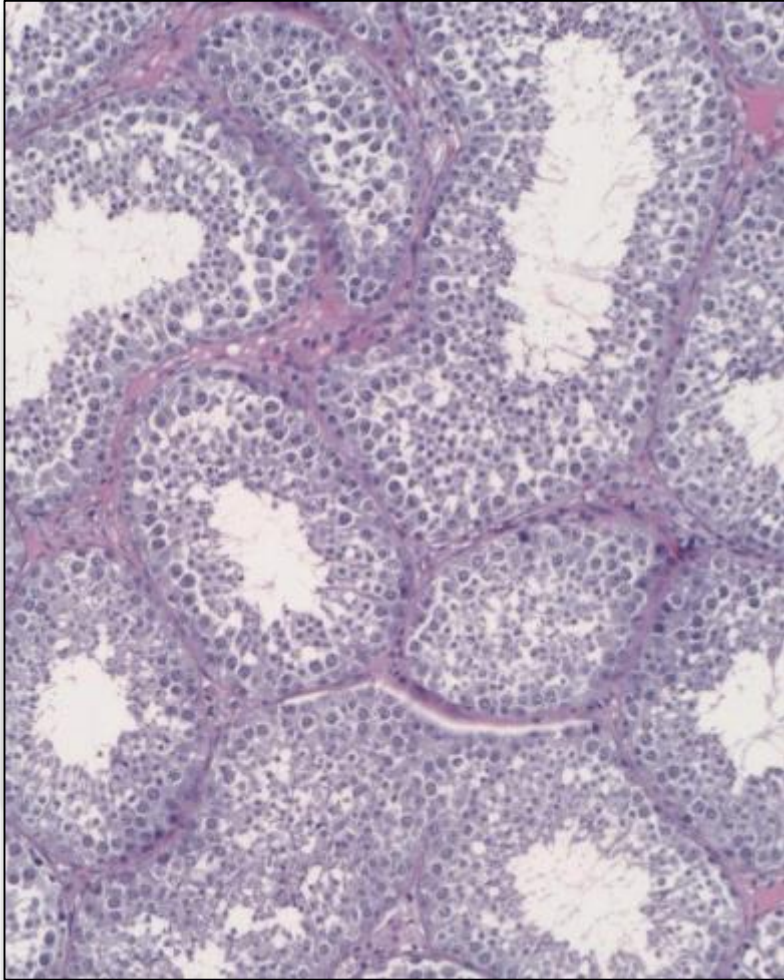


Bouin

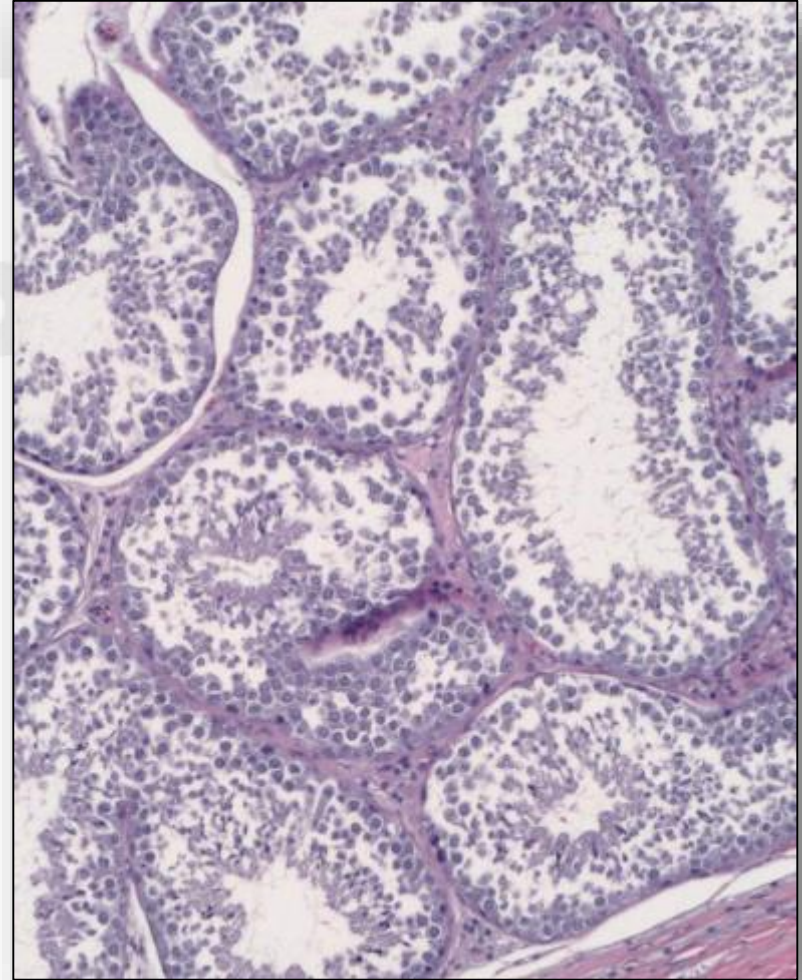


Range of fixation artifact

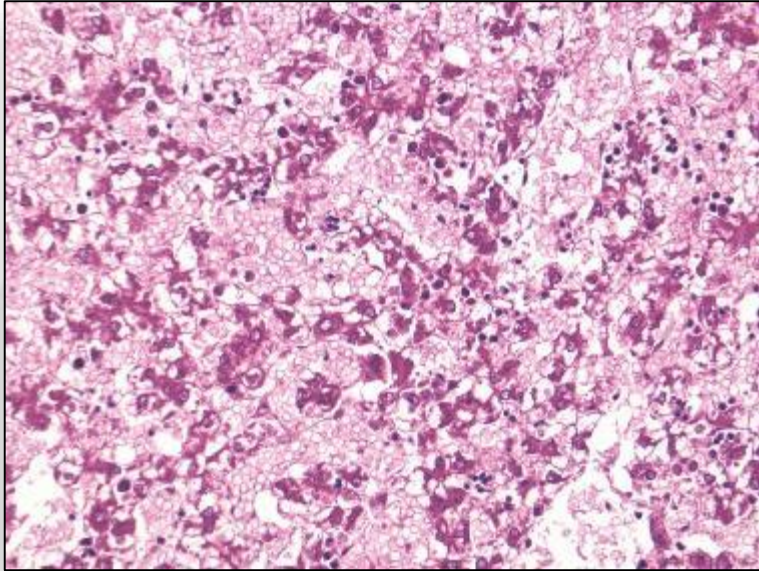
Minimal



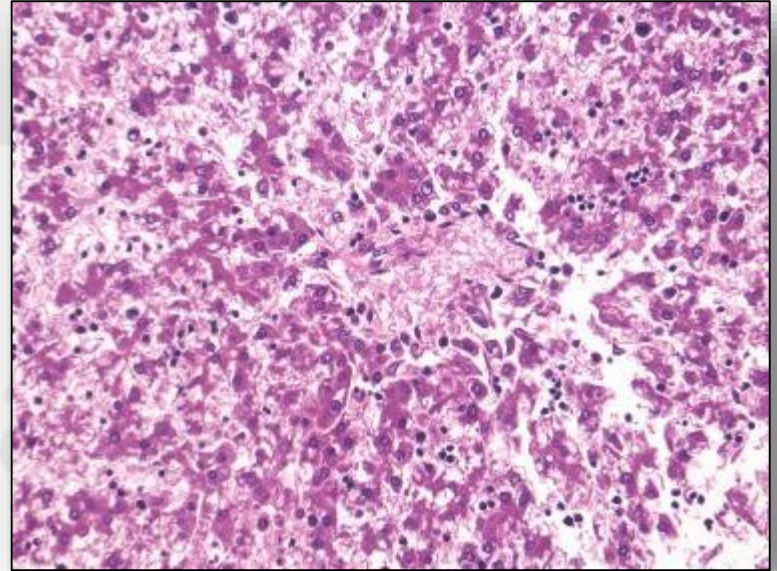
Moderate



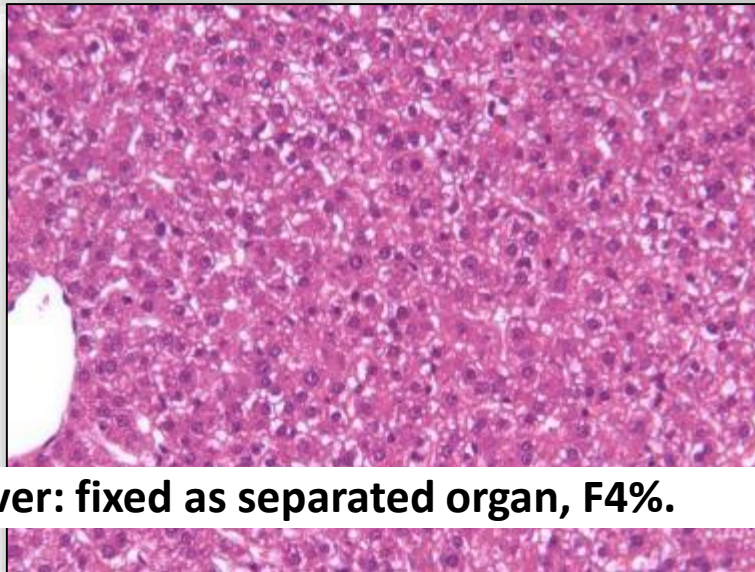
Artifacts by Fixation: Formaldehyde vs Ethanol



**Fetal liver: in situ fixed,
ET70%.**

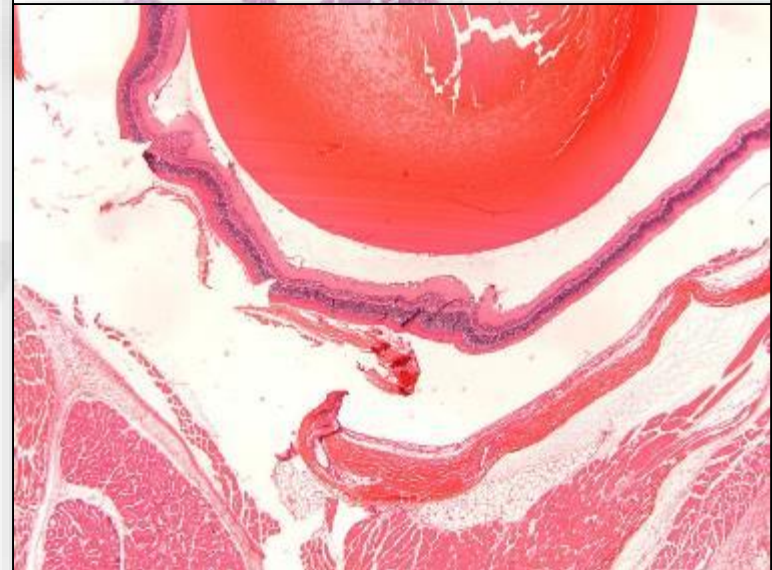
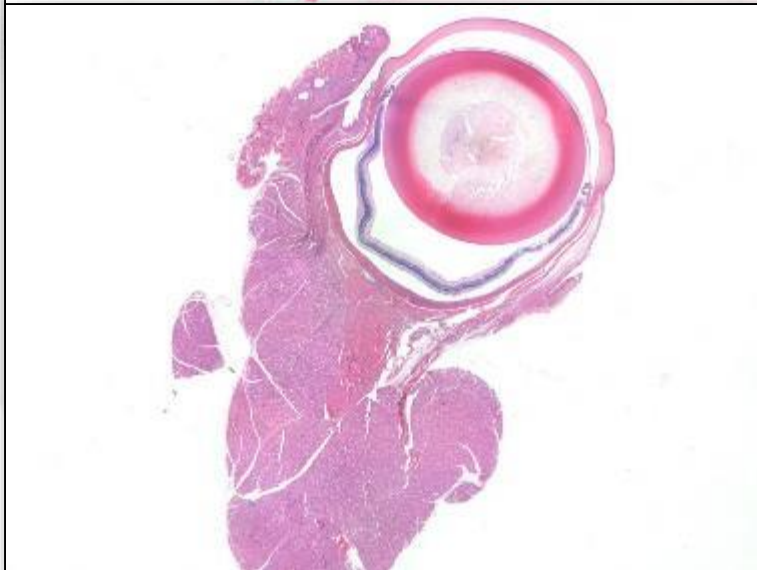
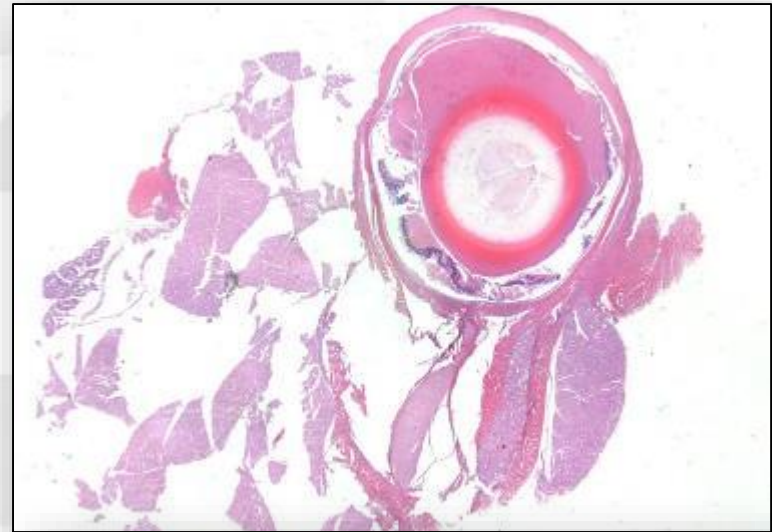
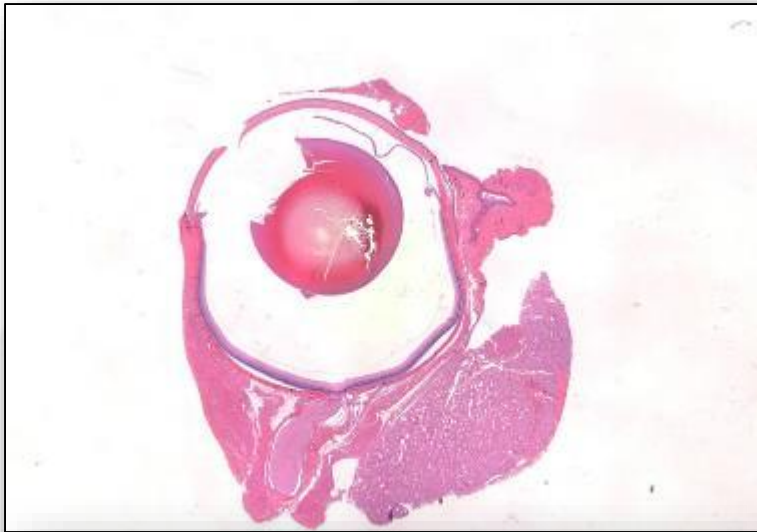


**Fetal liver: in situ fixed,
F4%.**

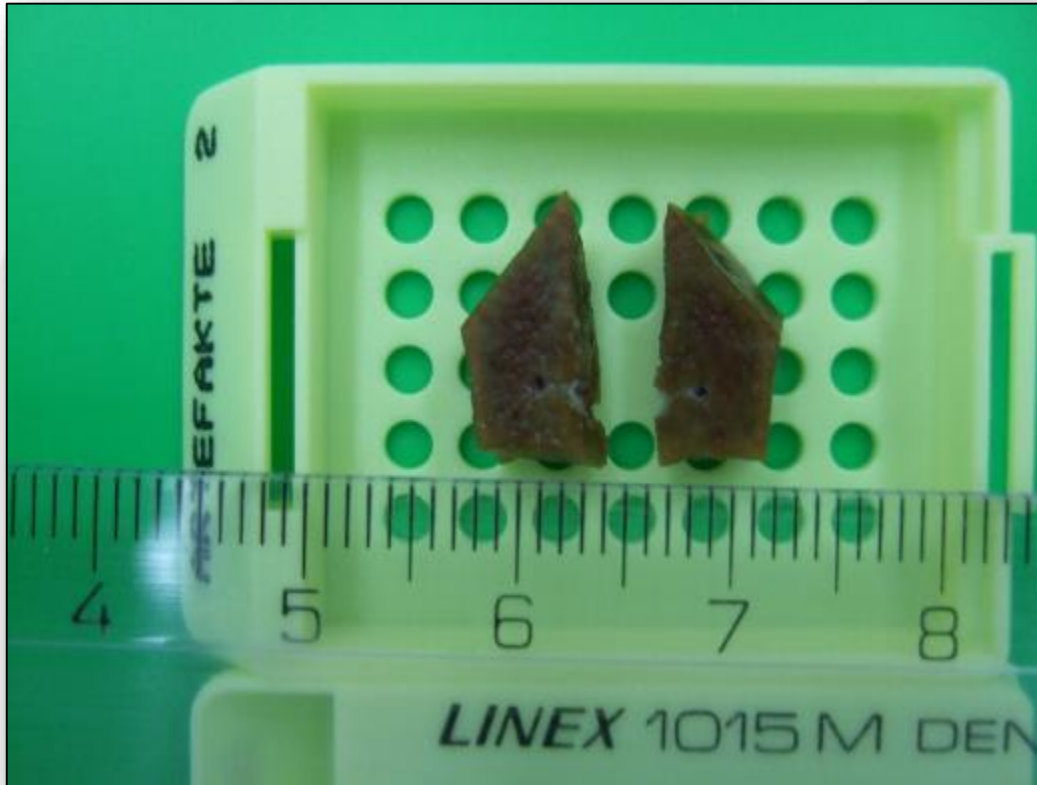

Fetal liver: fixed as separated organ, F4%.

Artifacts by Fixation: Davidson's vs Formaldehyde

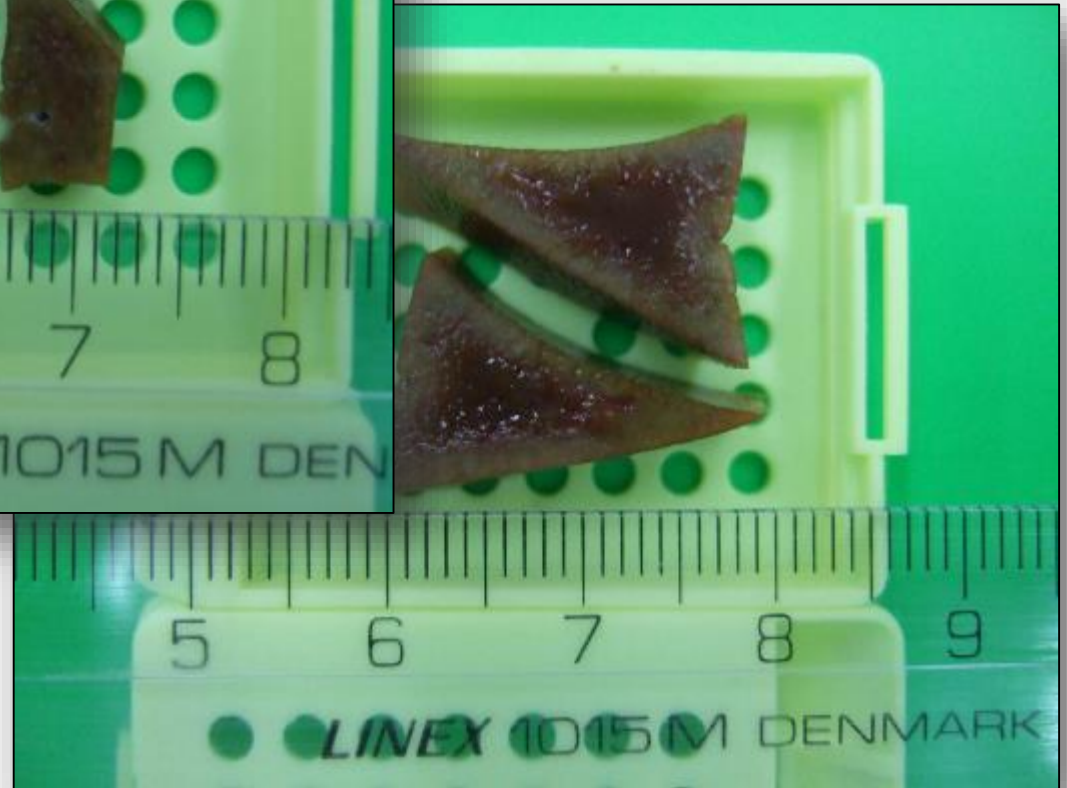


Thickness of Wet Tissues for Fixation



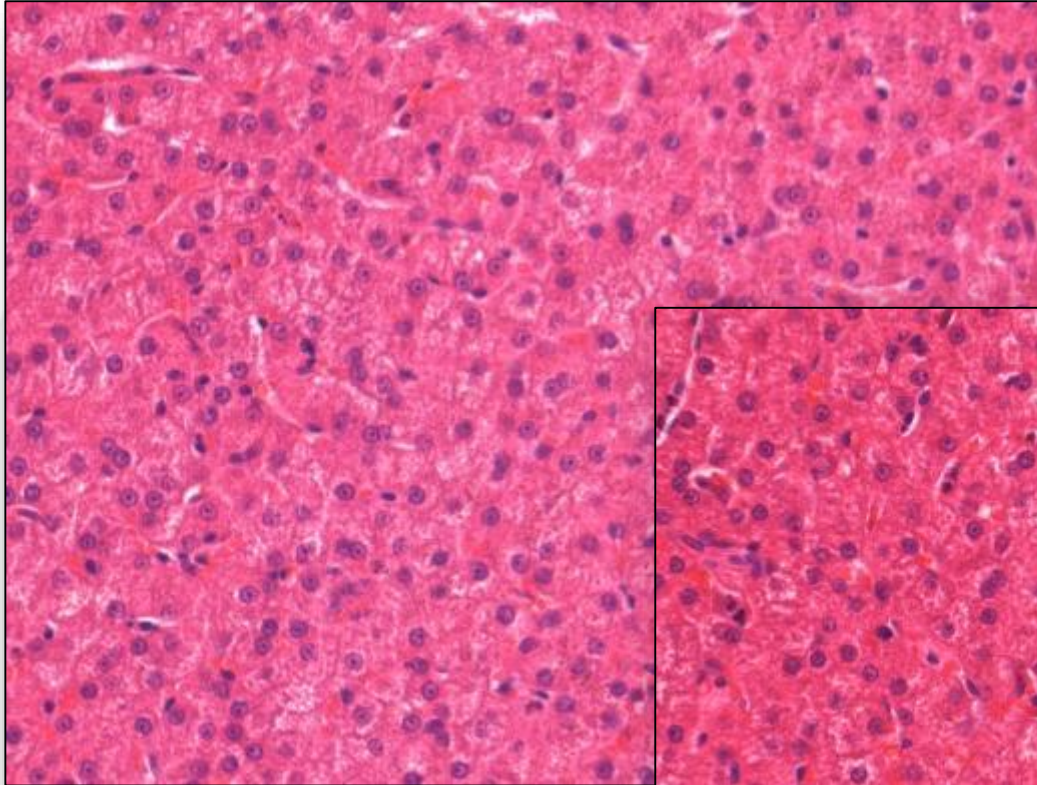
**Liver: block 5x5 mm,
F4%,1 day
Dog.**

**Liver: block 10x10
mm, F4%,1 day
Dog.**

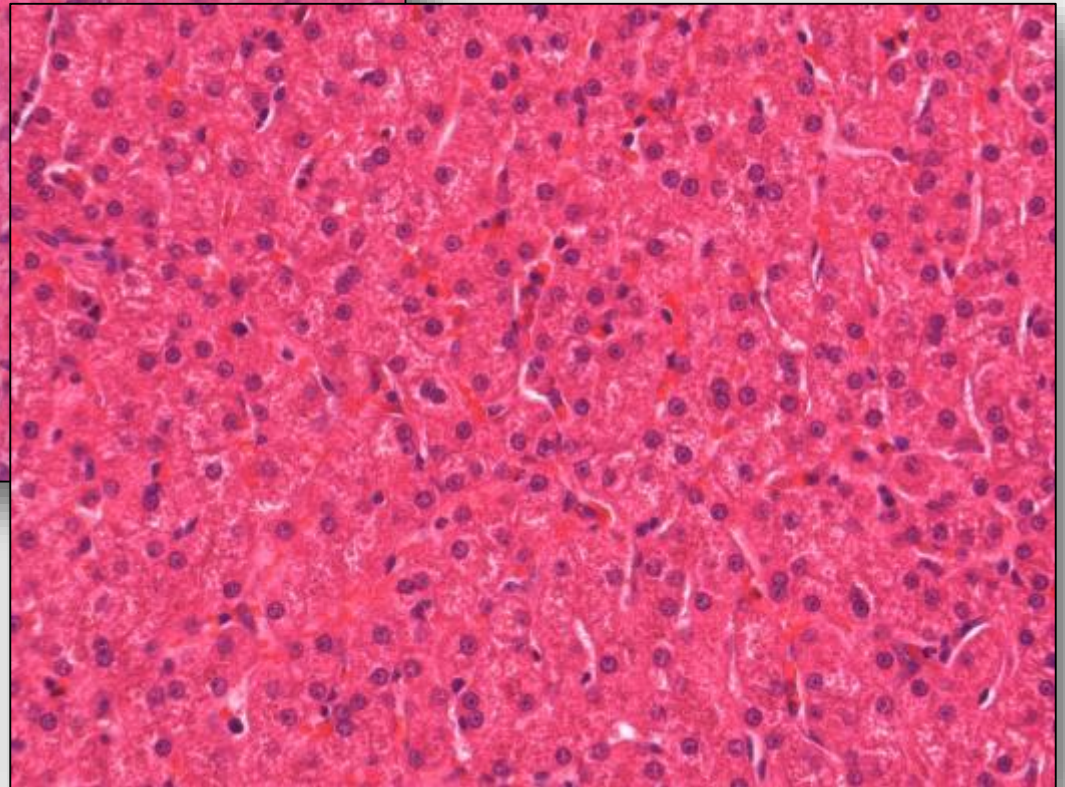


Thickness of Wet Tissues for Fixation

**Liver: block 10x10 mm, F4%, 1 day
Dog.**



**Liver: block 5x5 mm,
F4%, 1 day
Dog.**

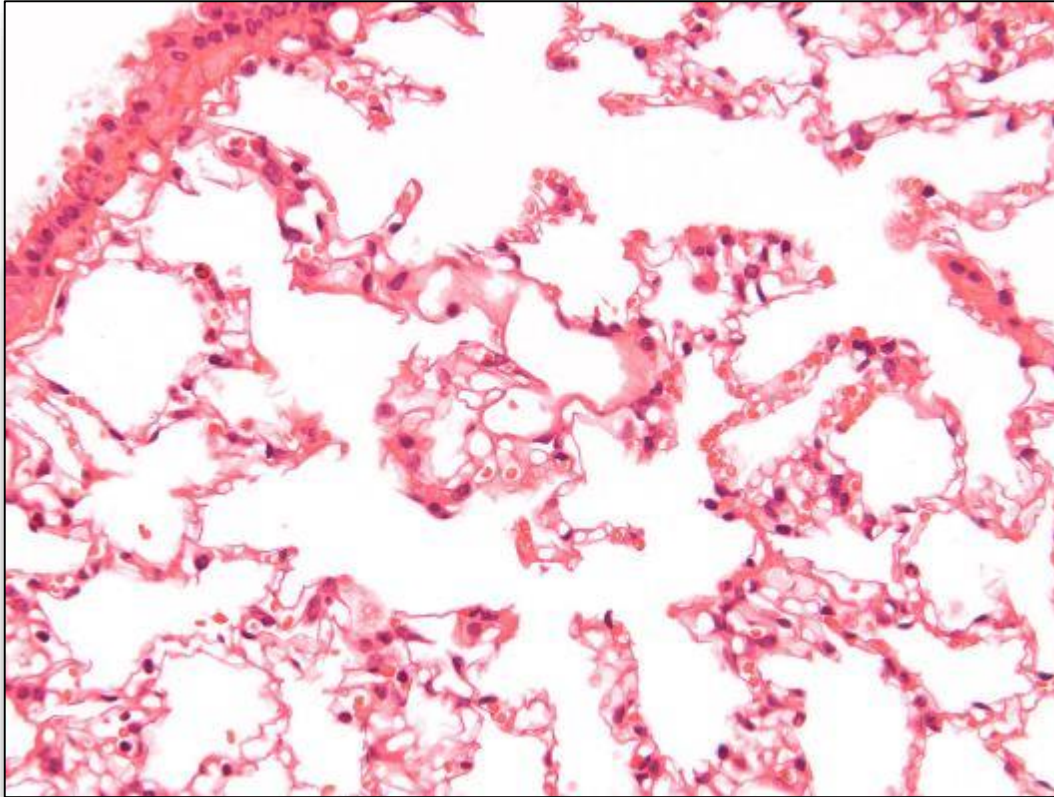


Fixation techniques may cause misinterpretation

- **Perfusion vs immersion fixation causes different appearance of morphological structures in tissues.**

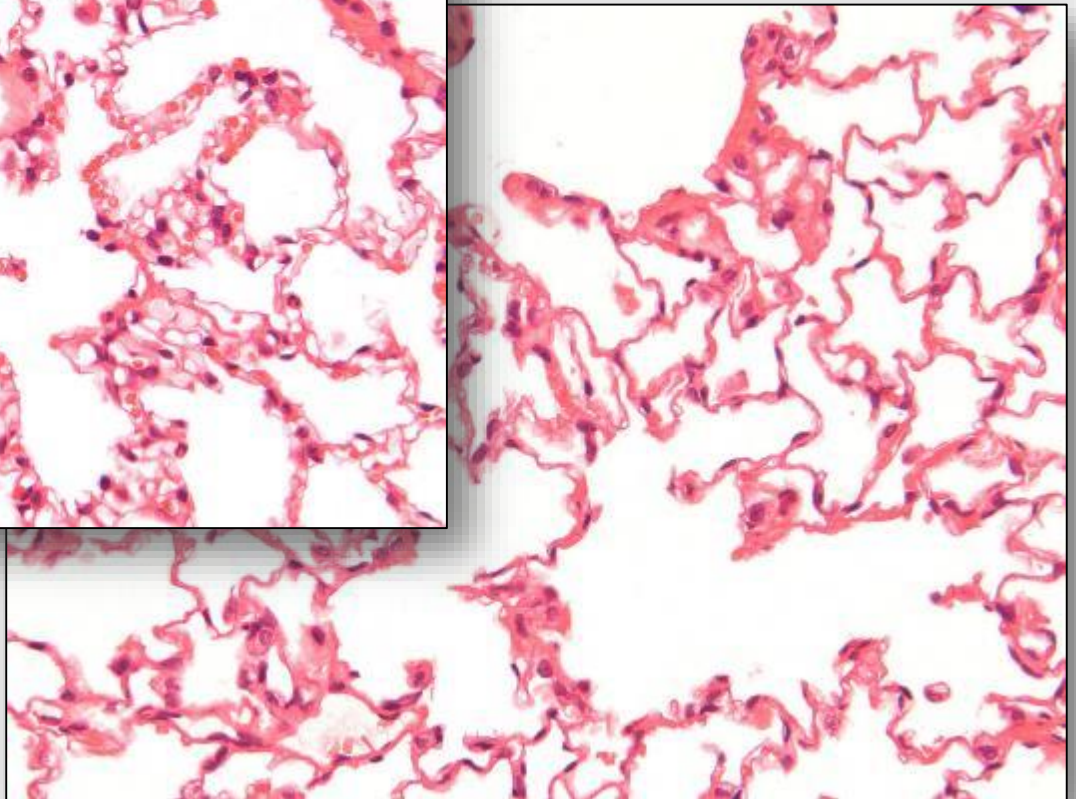
AnaPath

Perfusion with Formaldehyde

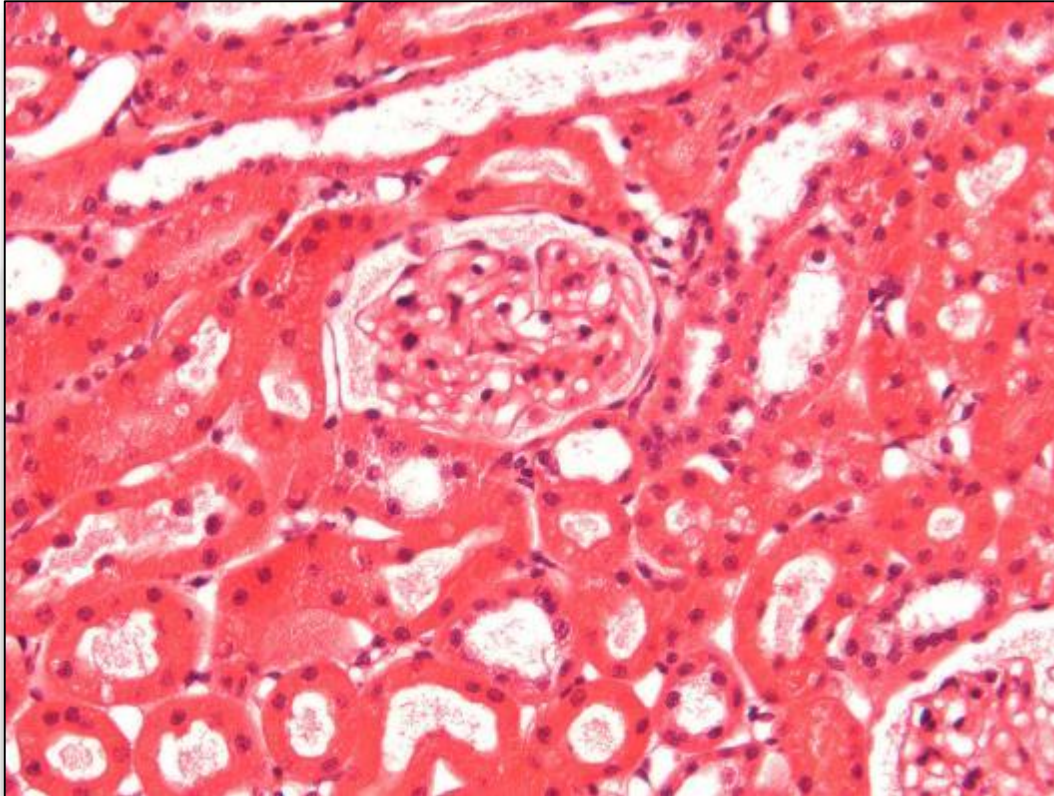


**Lung: perfusion,
F4%.**

Lung: inflation, F4%.

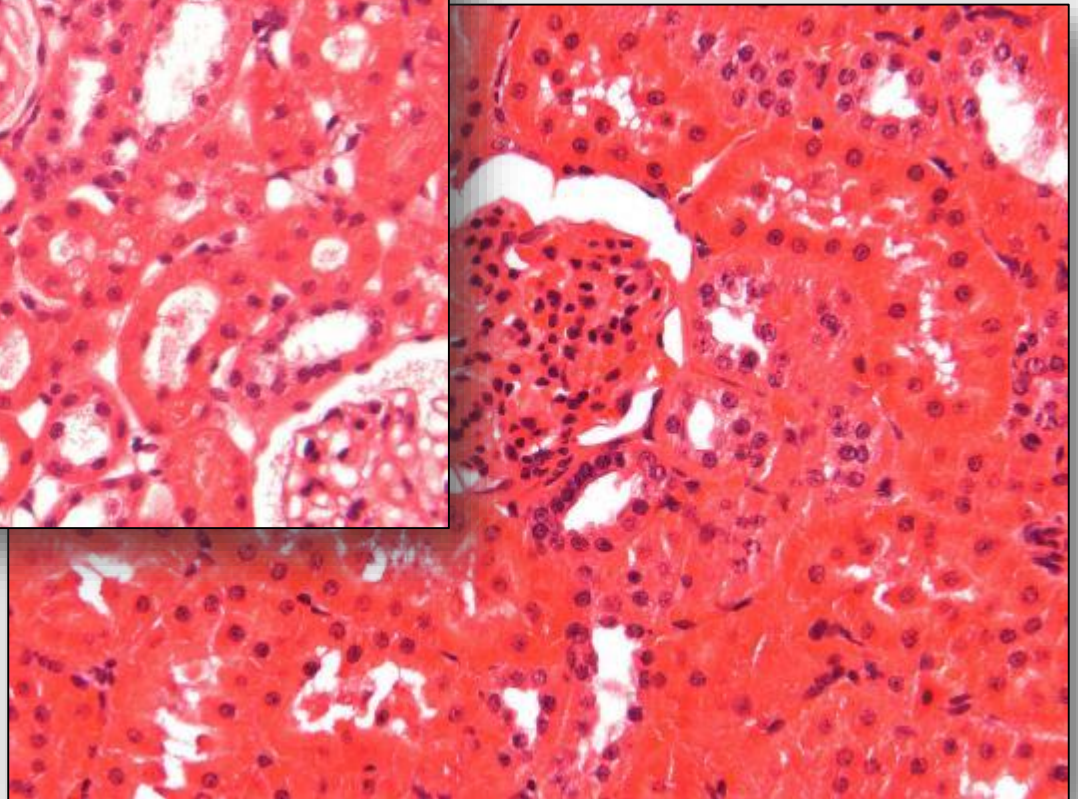


Perfusion with Formaldehyde

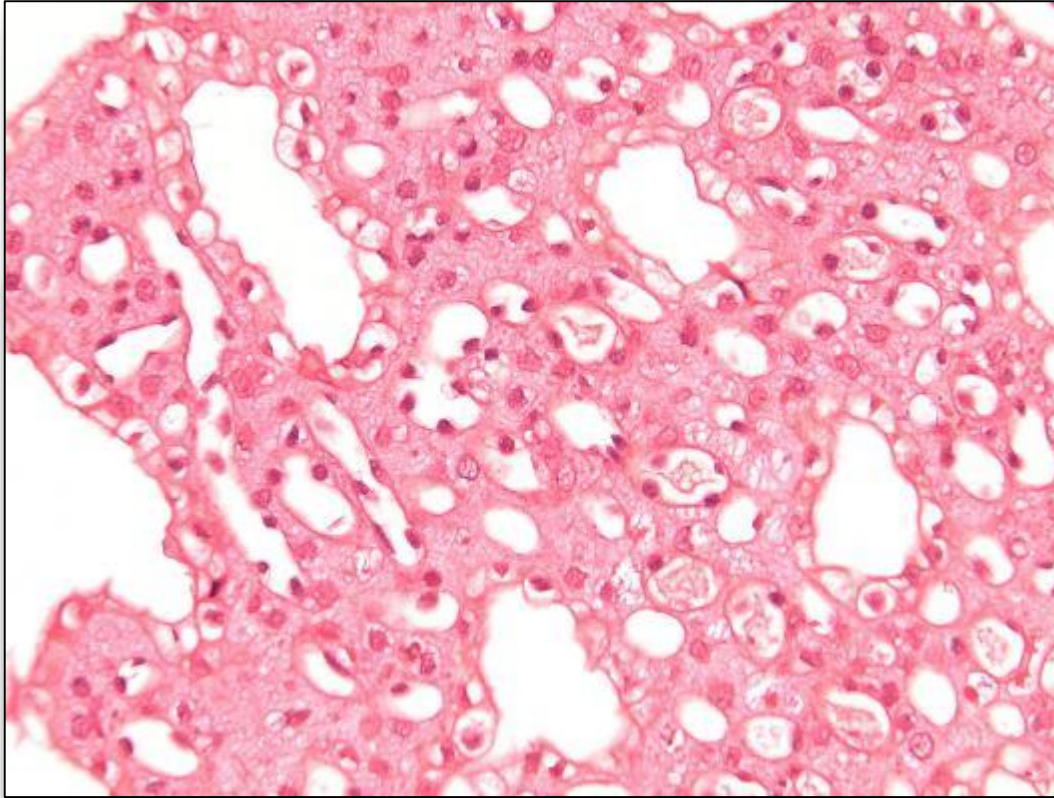


**Kidney: immersion,
F4%.**

**Kidney: perfusion,
F4%.**

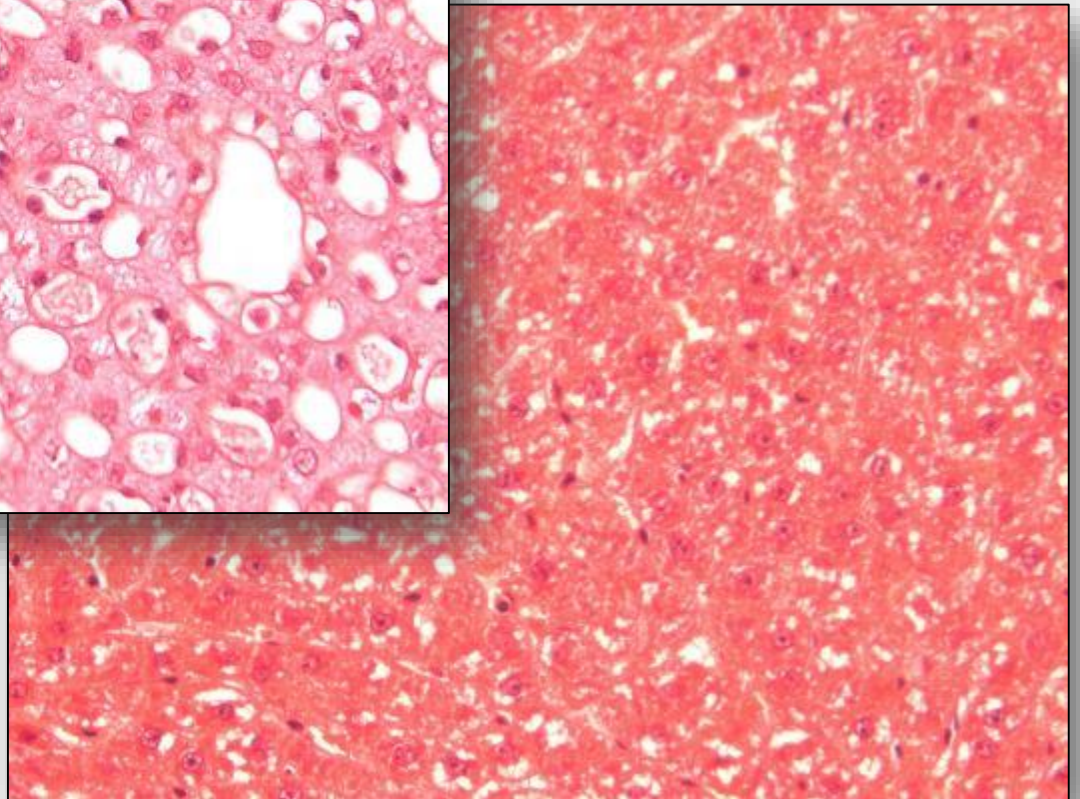


Perfusion with Formaldehyde



**Liver: perfusion,
F4%.**

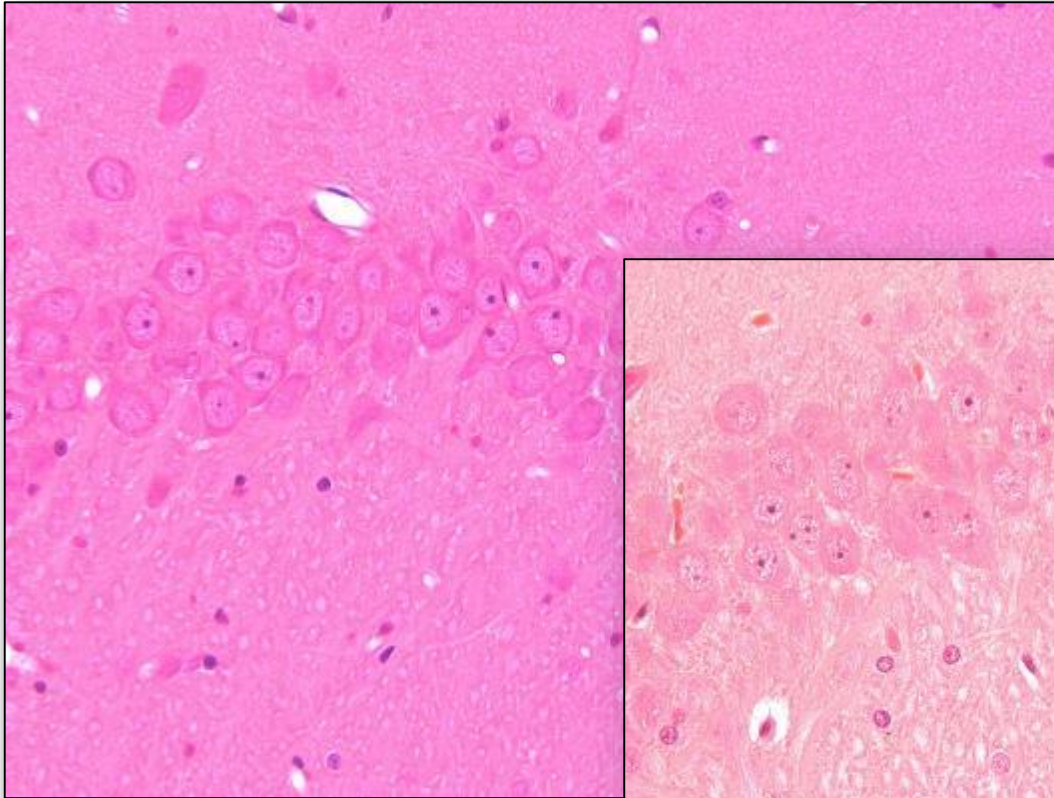
**Liver: immersion,
F4%.**



Fixation techniques may cause misinterpretation

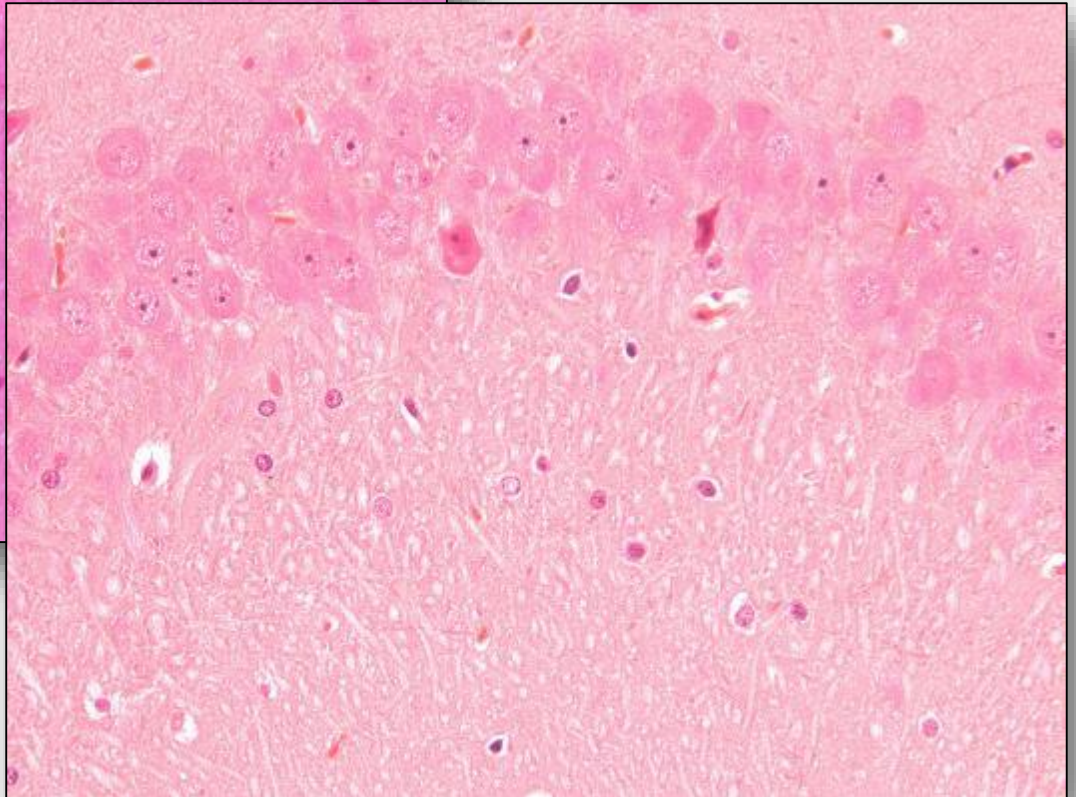
- **Perfusion technique is an absolute MUST in neurotoxicity studies.**
- **Dark stained neurons in immersion fixed brains may cause overestimations and wrong settings of NOEL/NOAEL!**

Perfusion with Formaldehyde

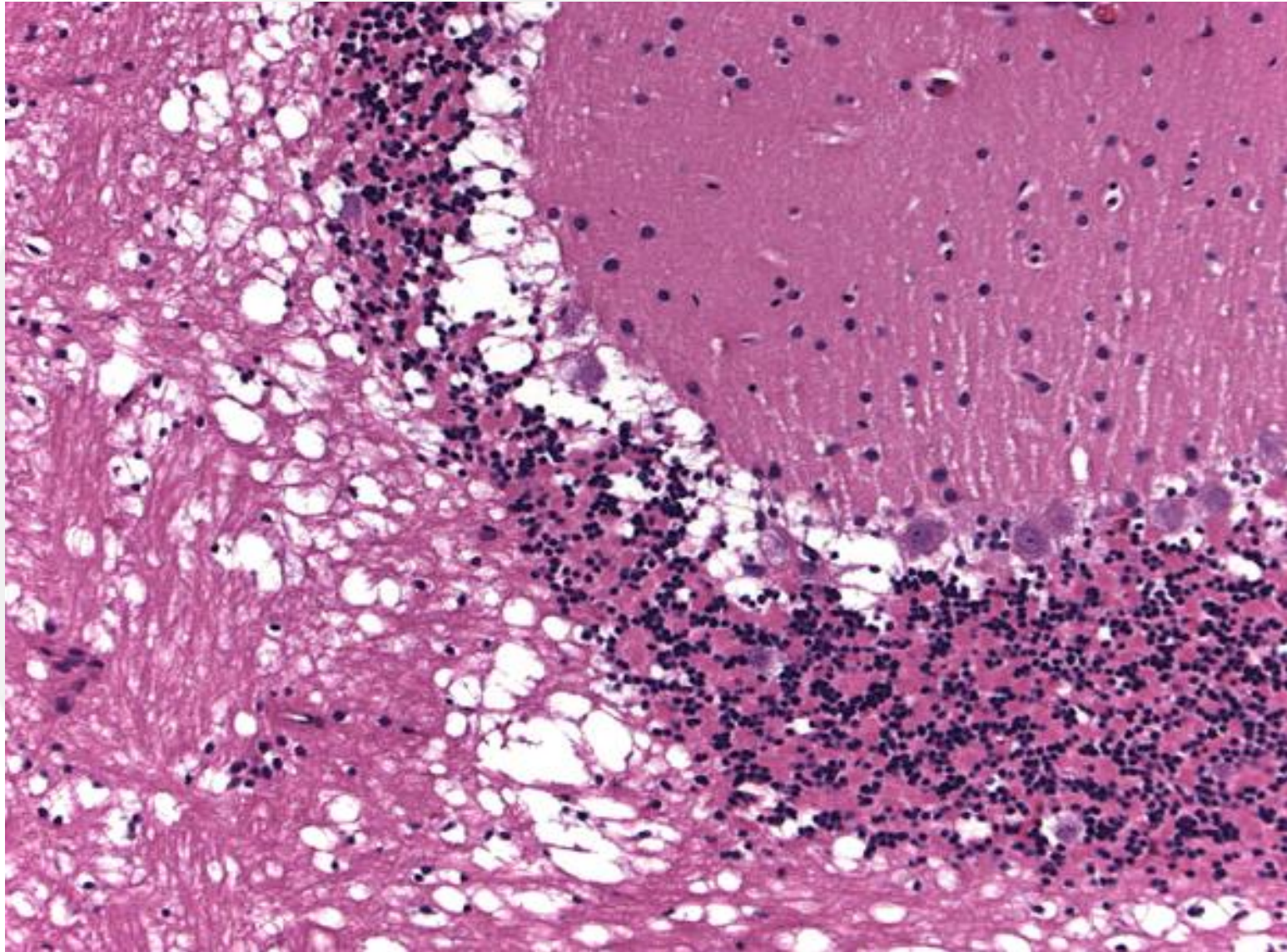


**Brain: perfusion,
F4%.**

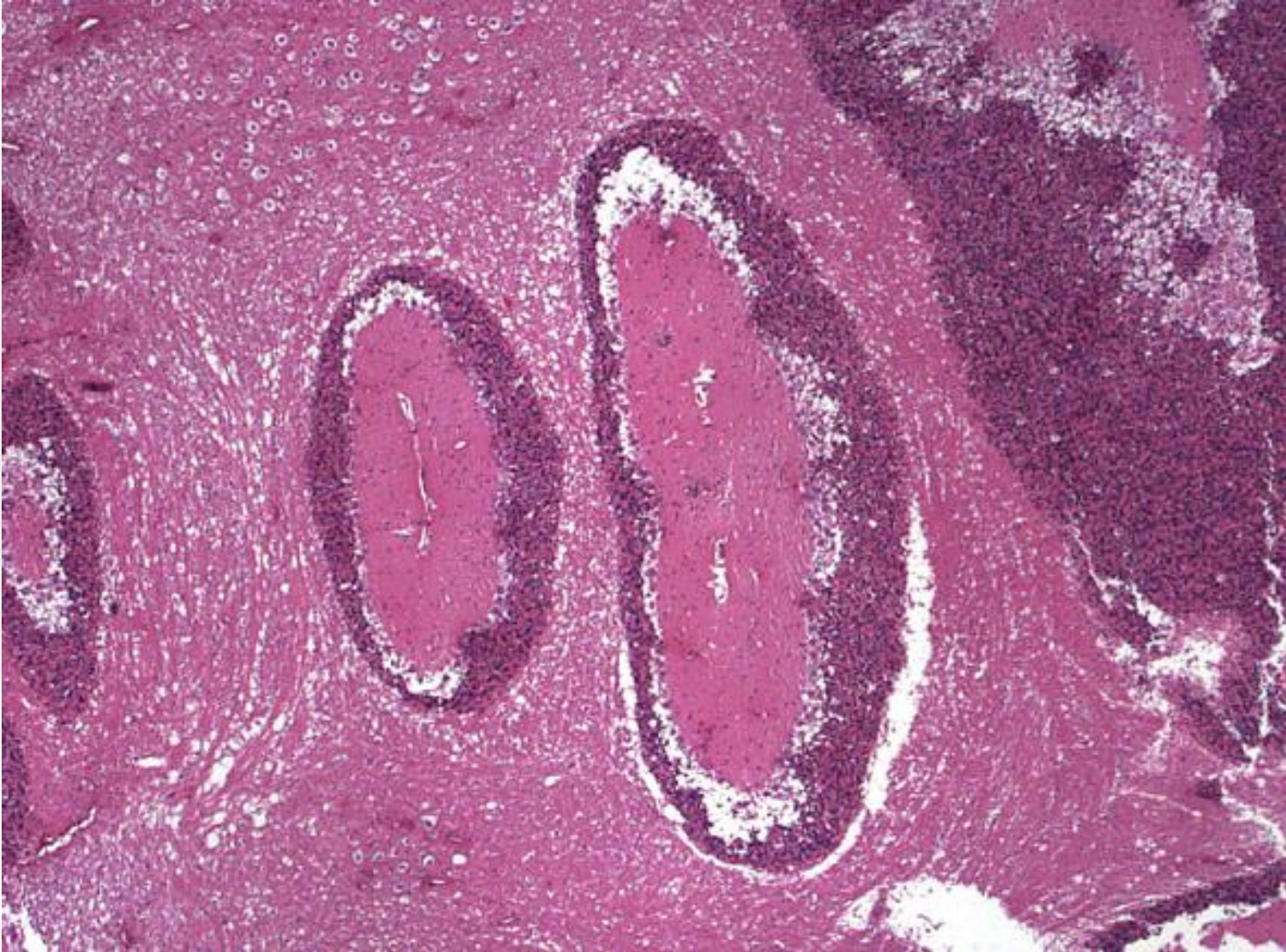
**Brain: immersion,
F4%.**



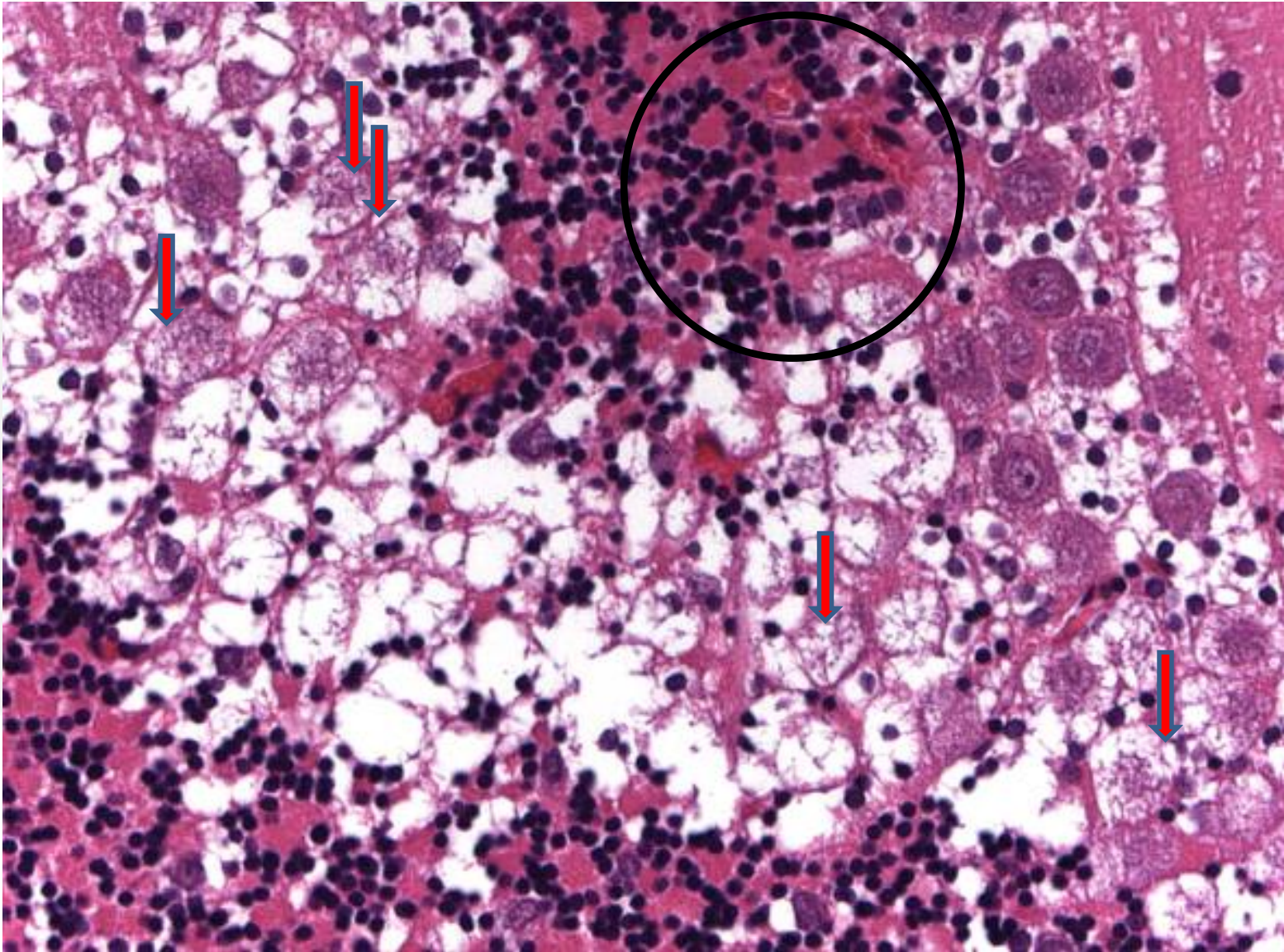
Artefacts by overpression in brain



Artefacts by overpression in brain



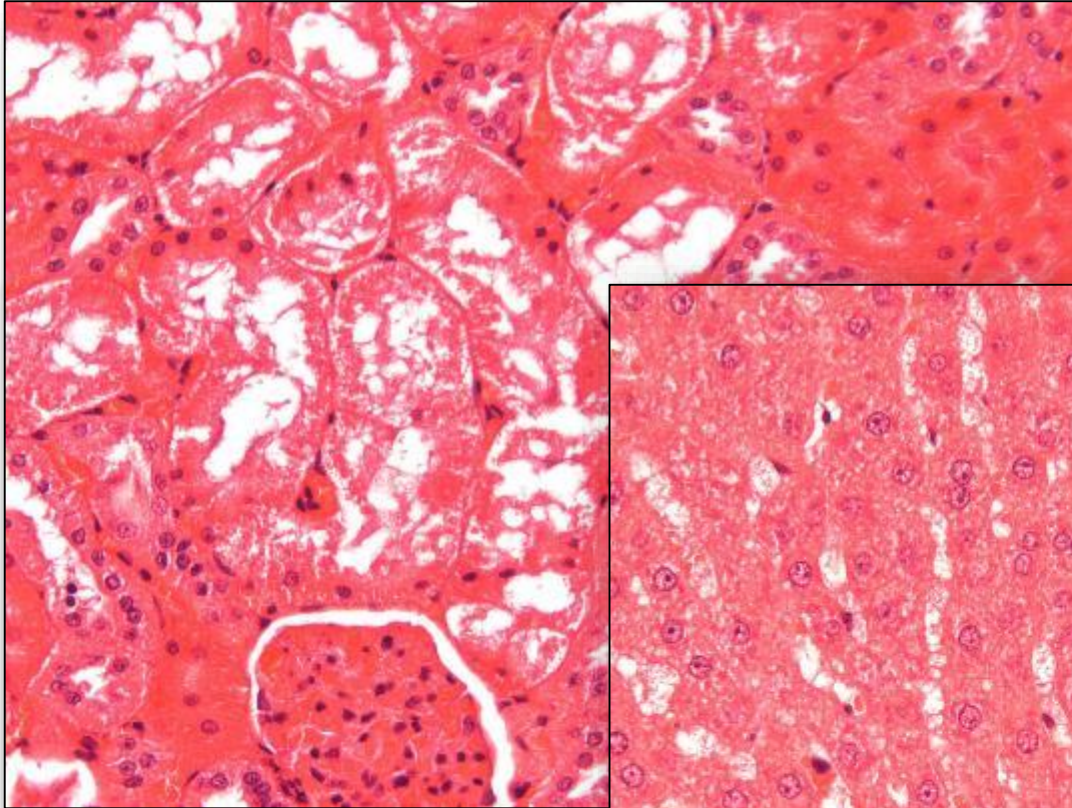
Artefacts by overpression in brain



Storage of decedent animals prior to necropsy

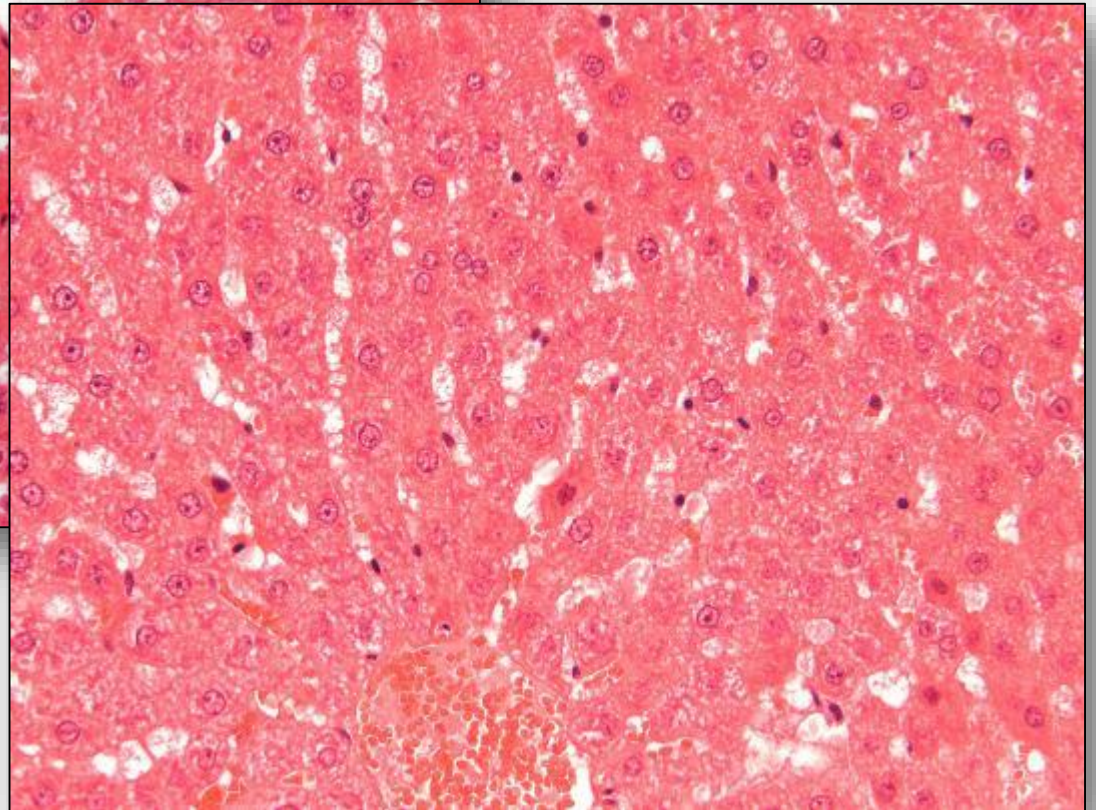
- **issue mainly in oncogenicity studies**
- **trained available personell**
- **weekend programs**
- **fridgerator is a possibilty but freezers are obsolete**

Cooled in fridgerator 5-8 °C

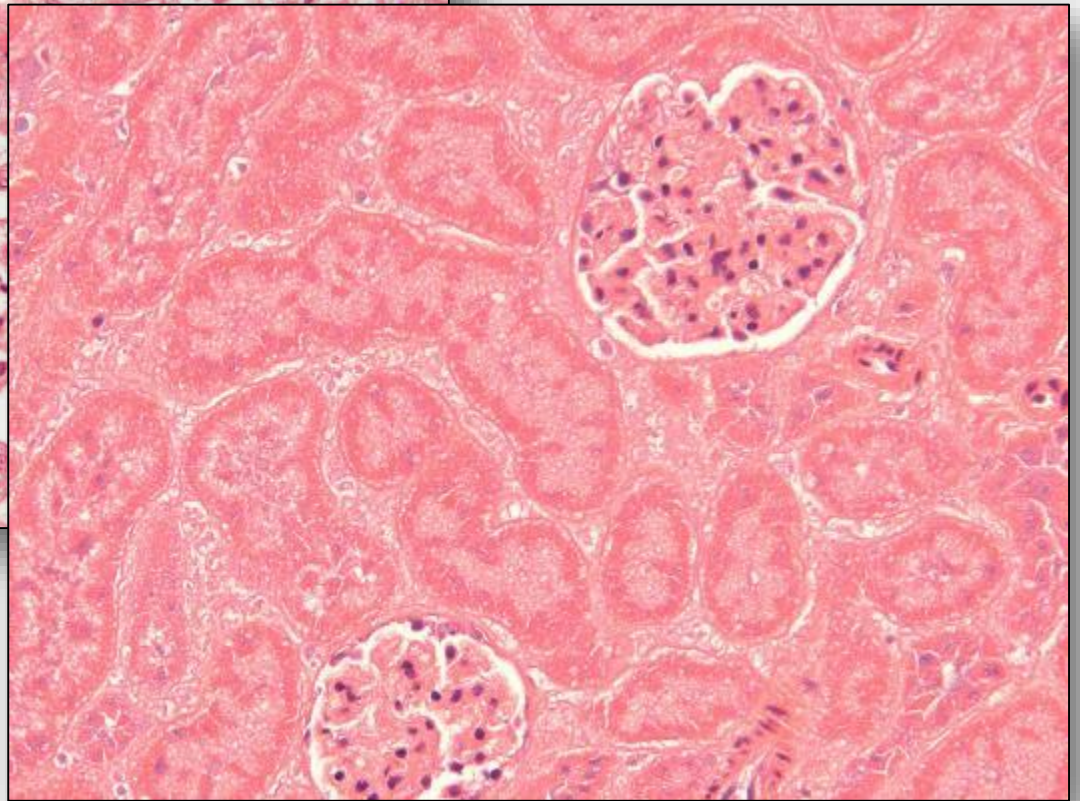
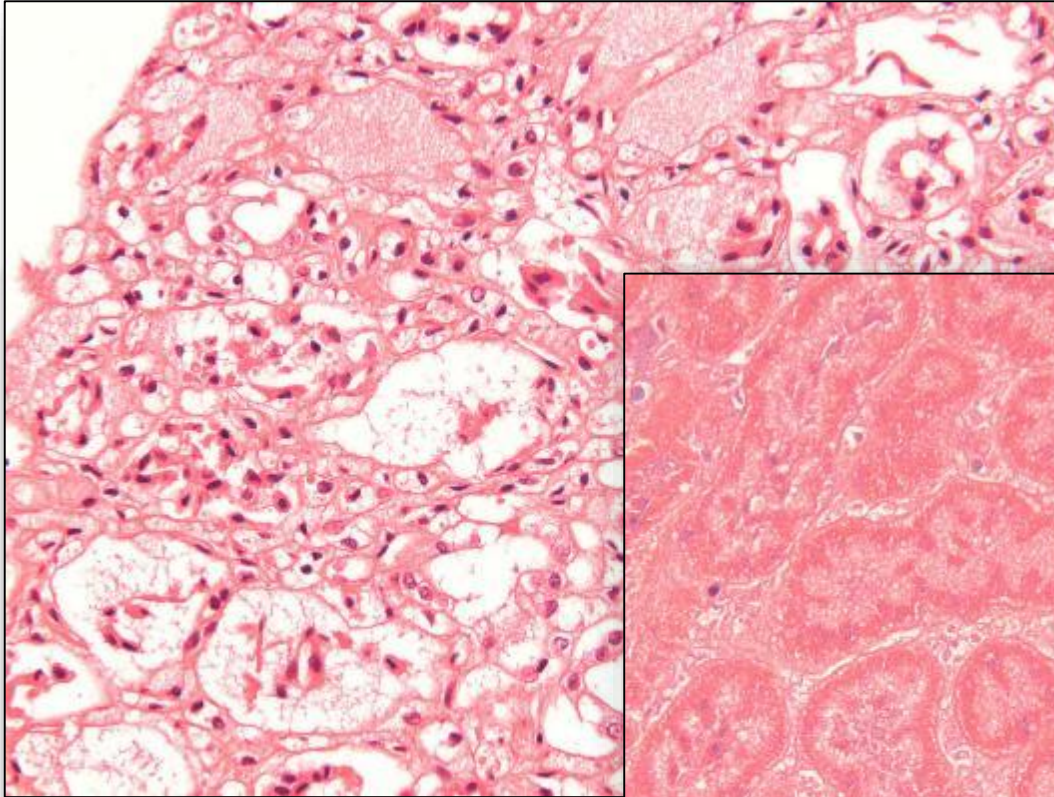


**Kidney: 24hr,
fridgerator, F4%.**

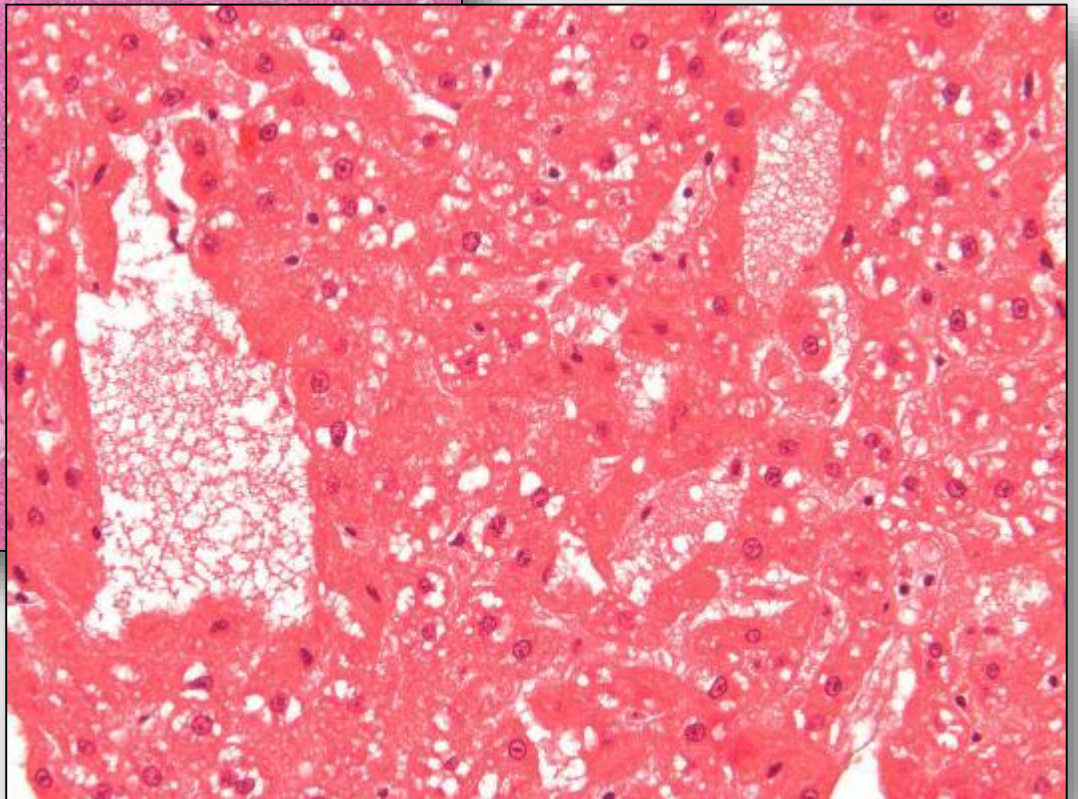
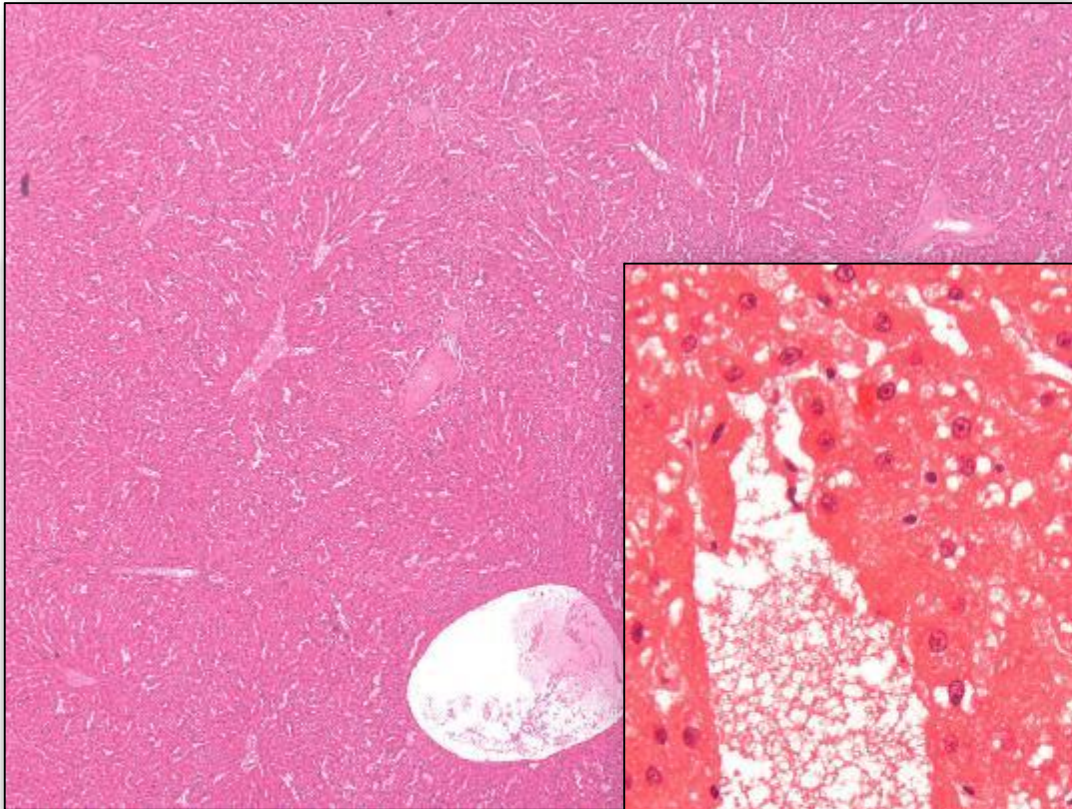
**Liver: 24hr,
fridgerator, F4%.**



Frozen Tissues: Kidney



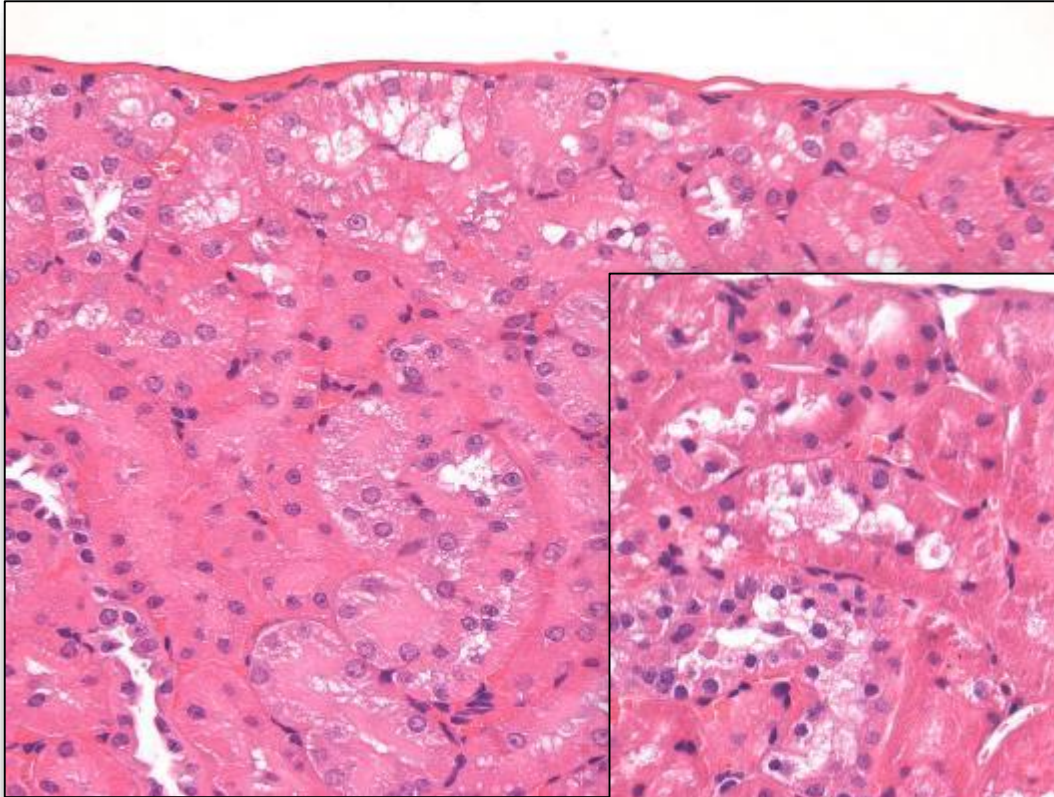
Frozen Tissues: Liver



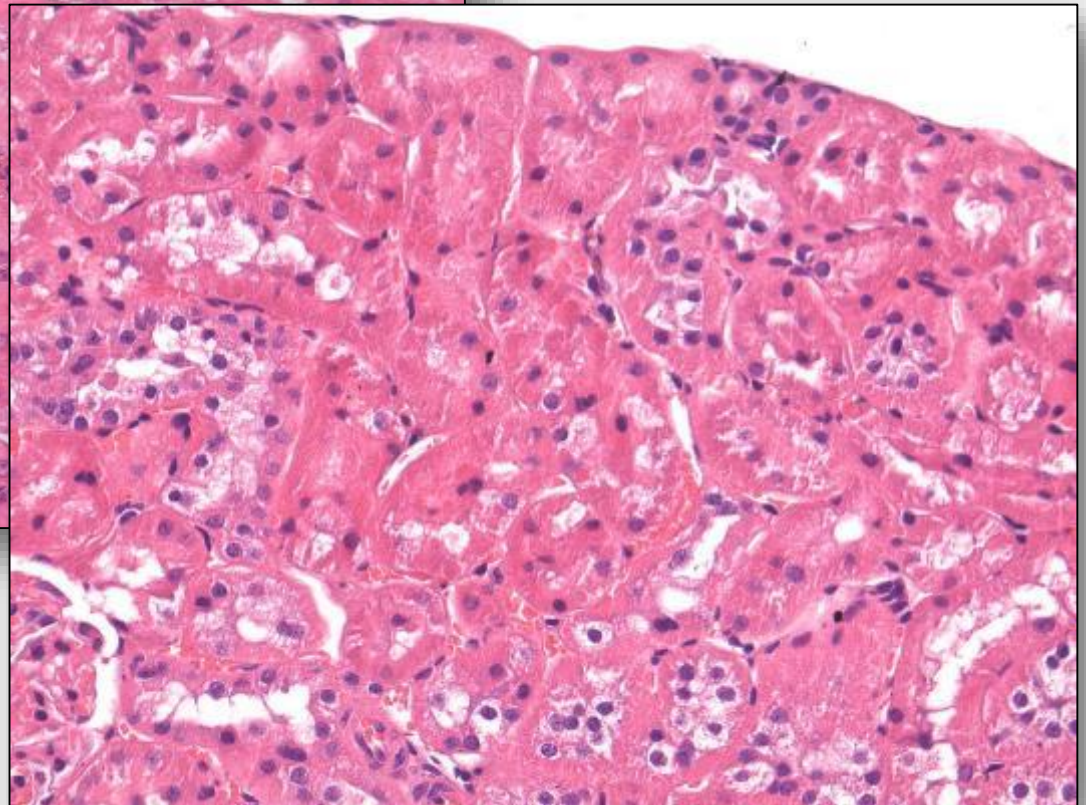
Postmortal changes may cause in misinterpretation

- **Study on induced artifacts performed at Harlan incl.**
- **use of different fixatives, fixation time, drying out of organs, cooling, freezing, autolysis etc.**
- **Inappropriate fixatives may cause alterations confused with induced lesions e.g. degeneration, necrosis etc.**

Drying Artifacts

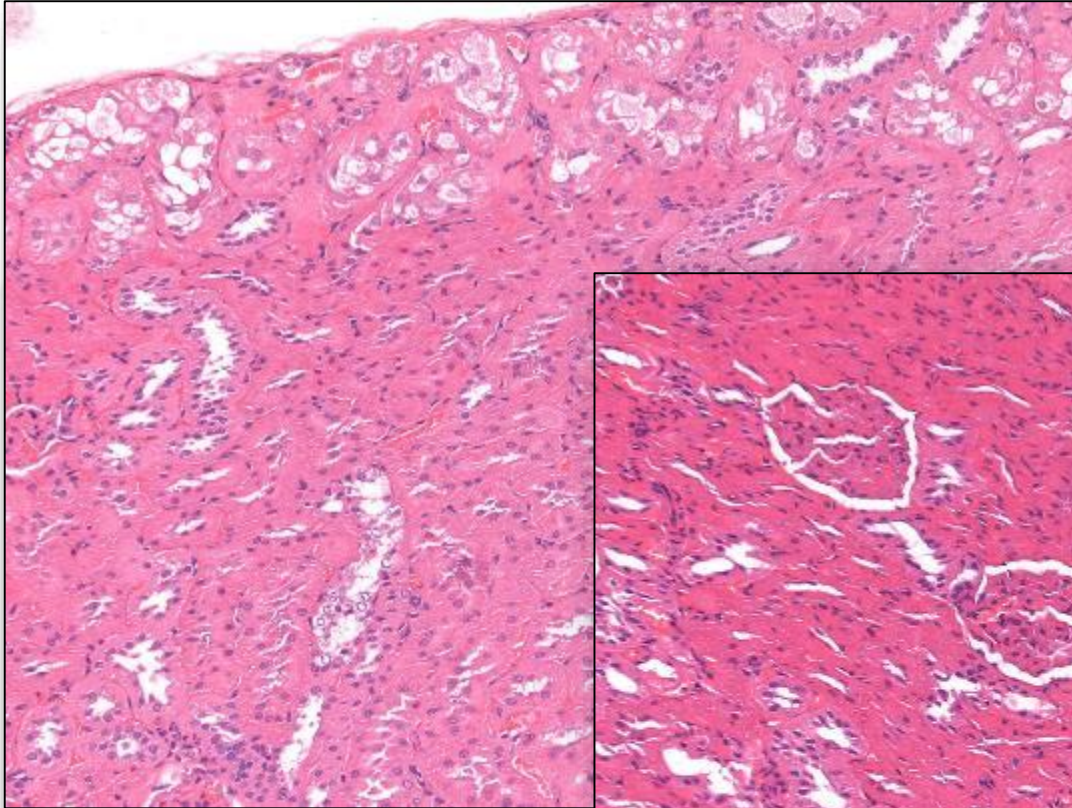


Kidney: 60', room temperature, F4%.



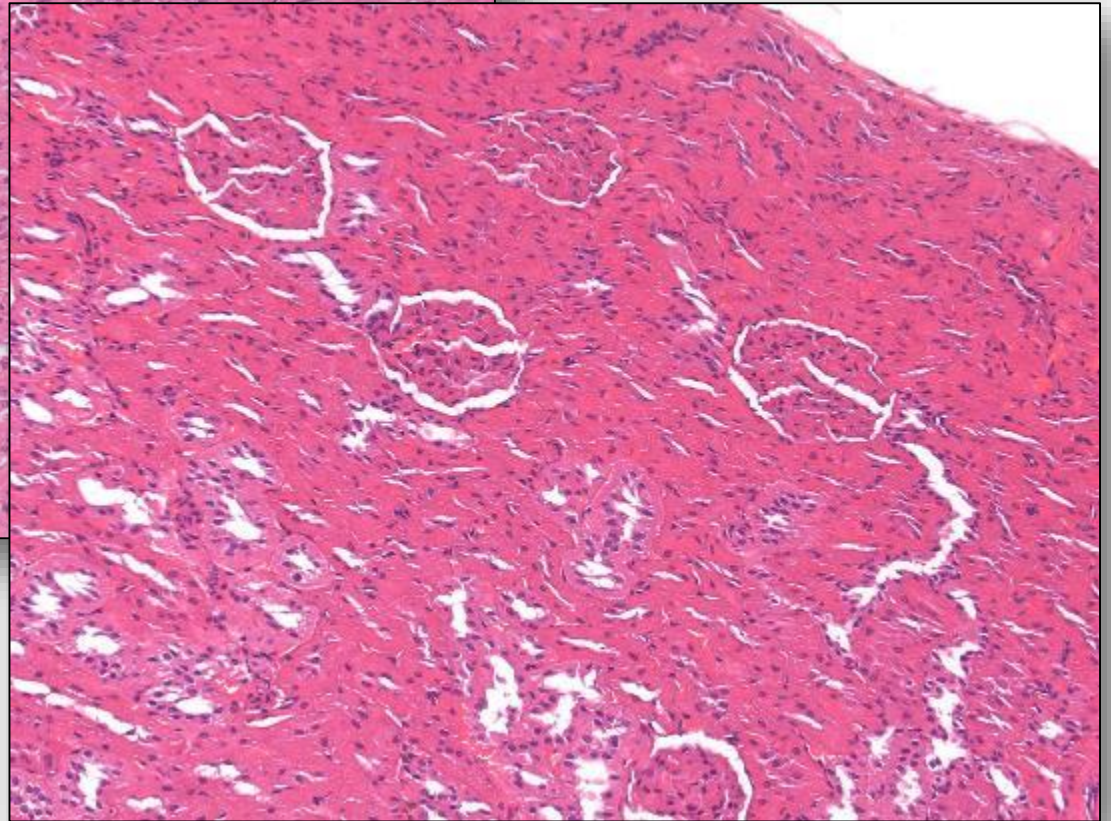
Kidney: 15', room temperature, F4%.

Autolysis

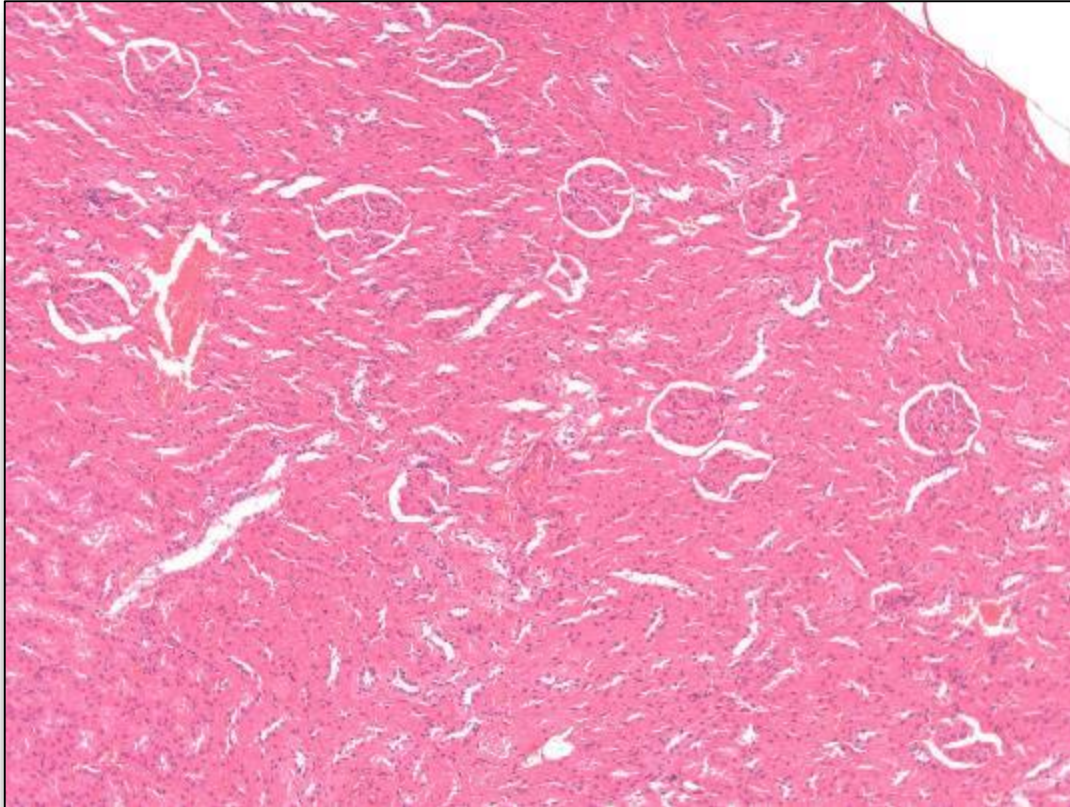


Kidney: 4hr, room temperature, F4%.

Kidney: 8hr, room temperature, F4%.

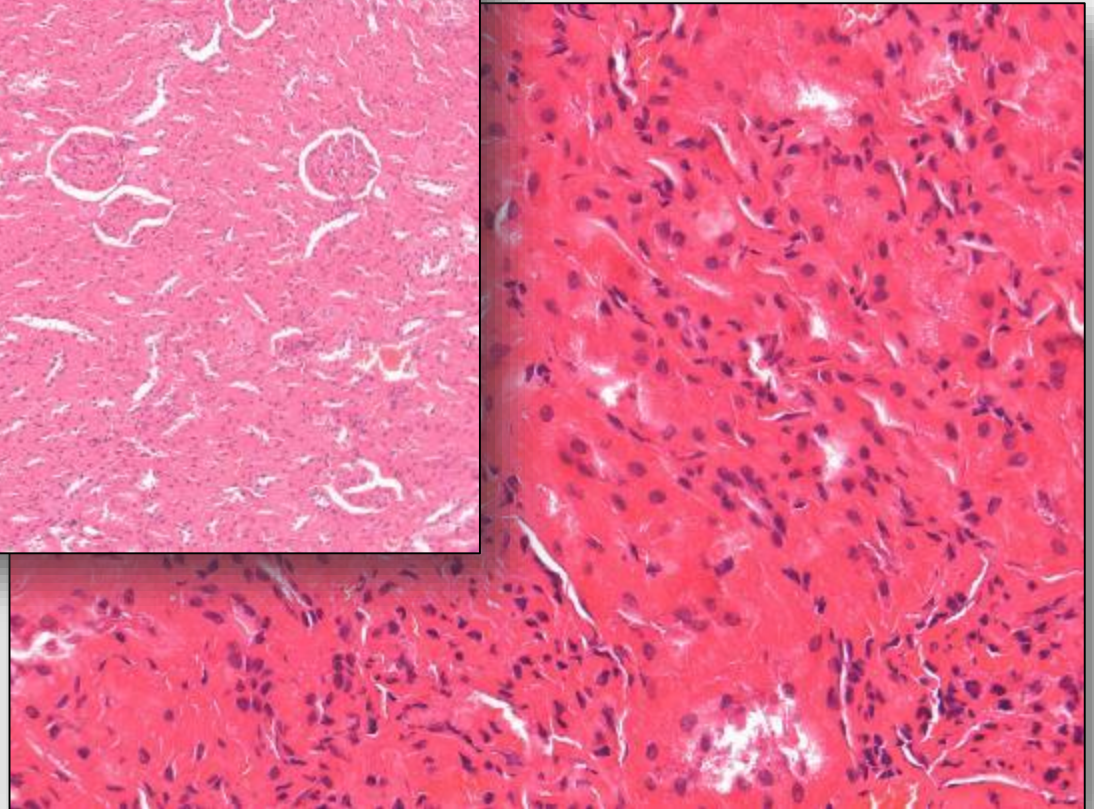


Autolysis

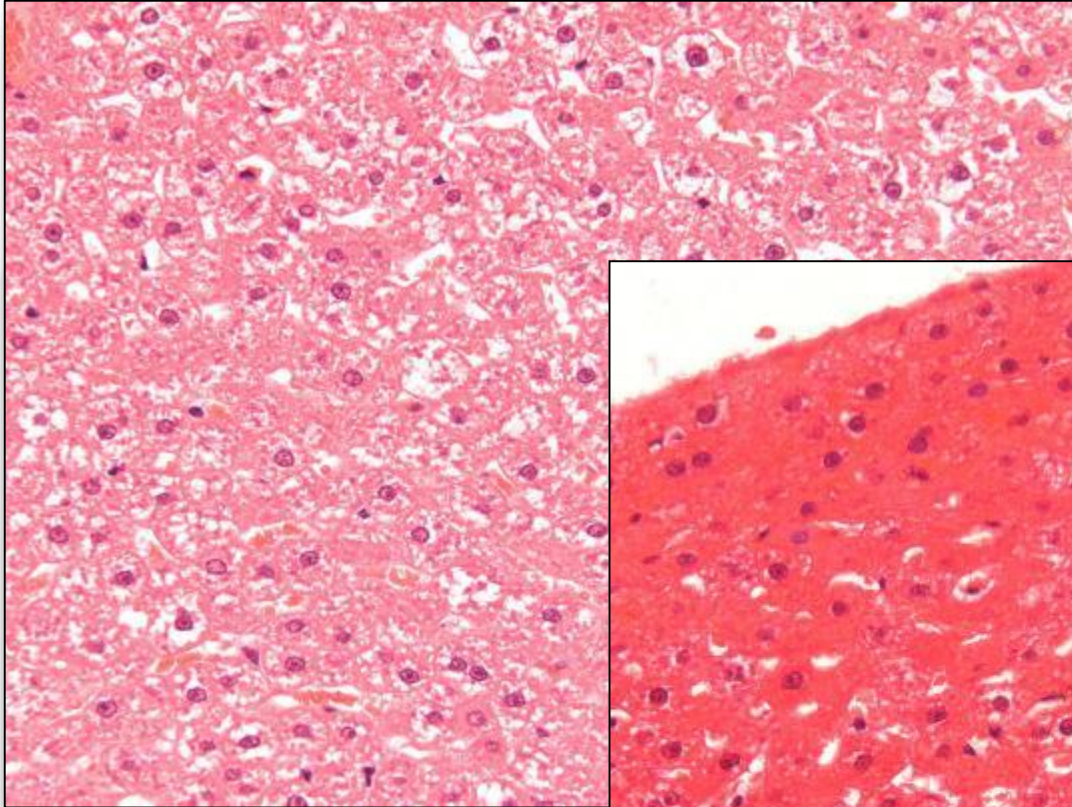


Kidney: 12hr, room temperature, F4%.

Kidney: 24hr, room temperature, F4%.

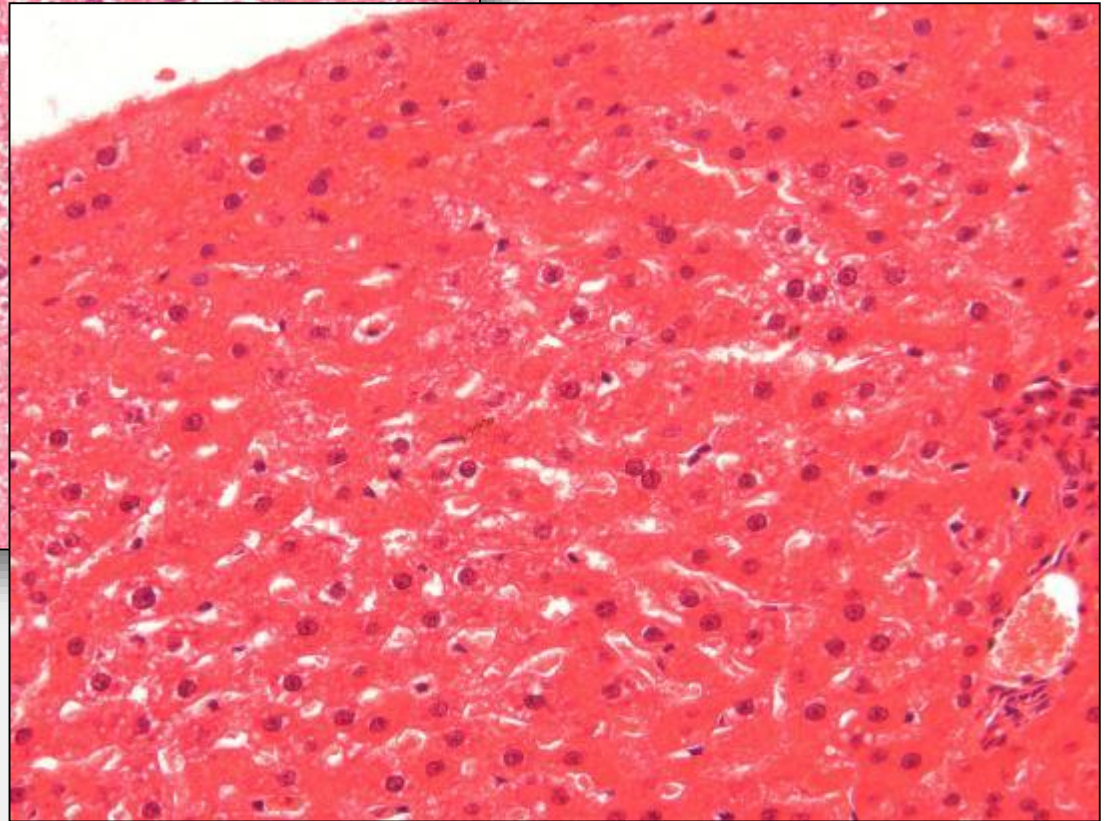


Autolysis

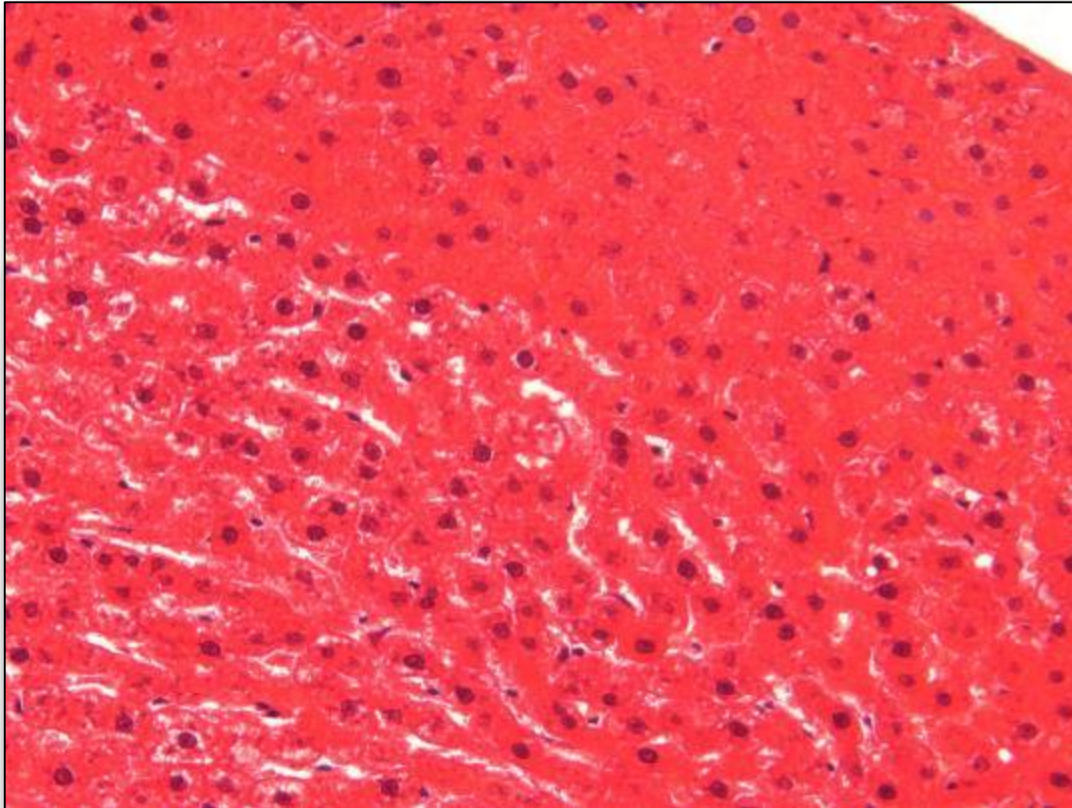


Liver: 4hr, room temperature, F4%.

Liver: 8hr, room temperature, F4%.

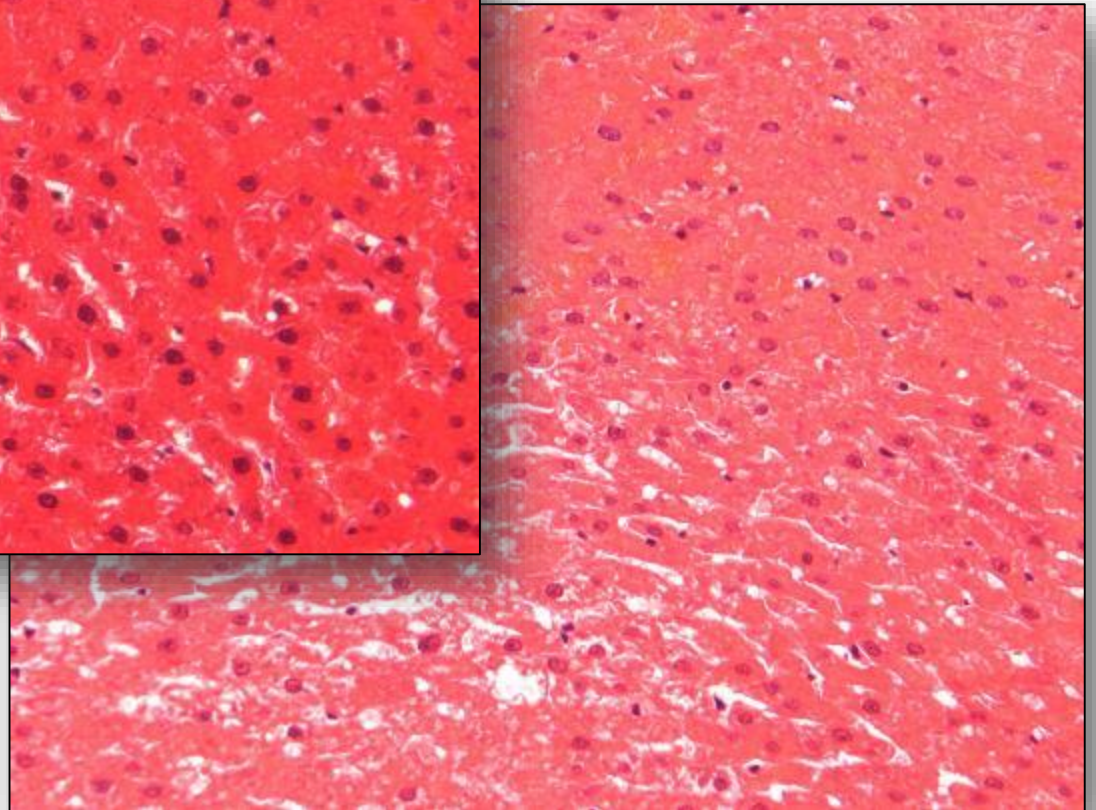


Autolysis

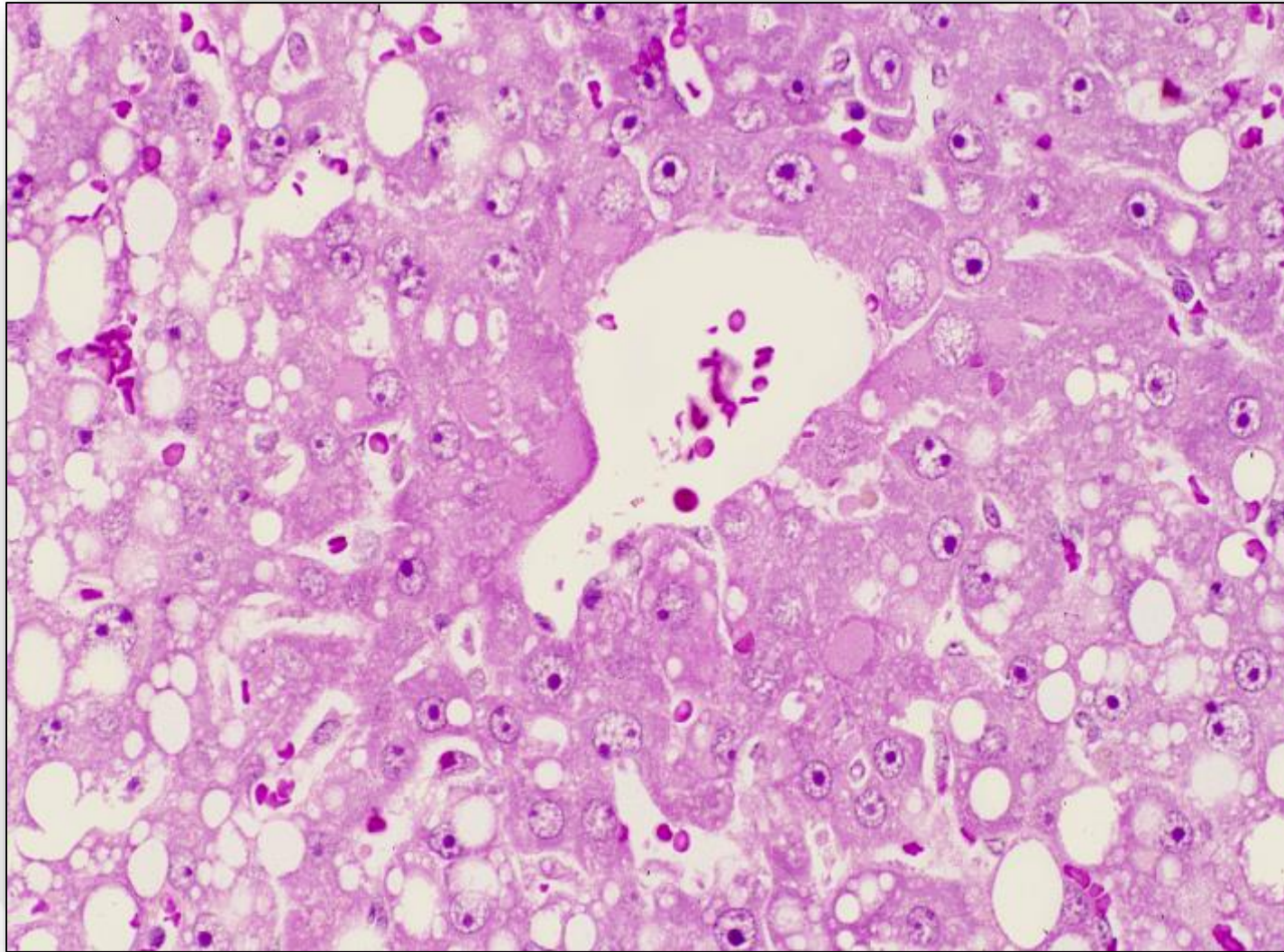


Liver: 12hr, room temperature, F4%.

Liver: 24hr, room temperature, F4%.



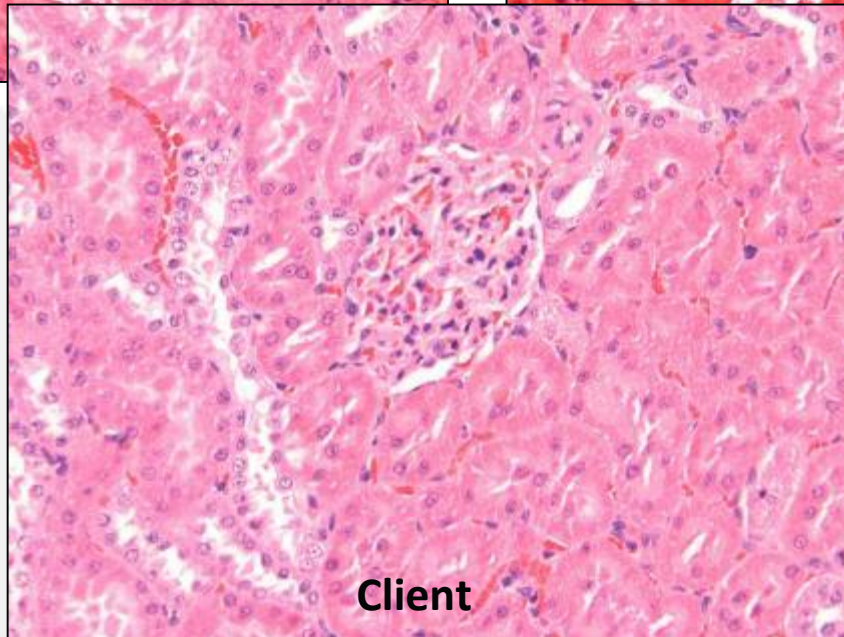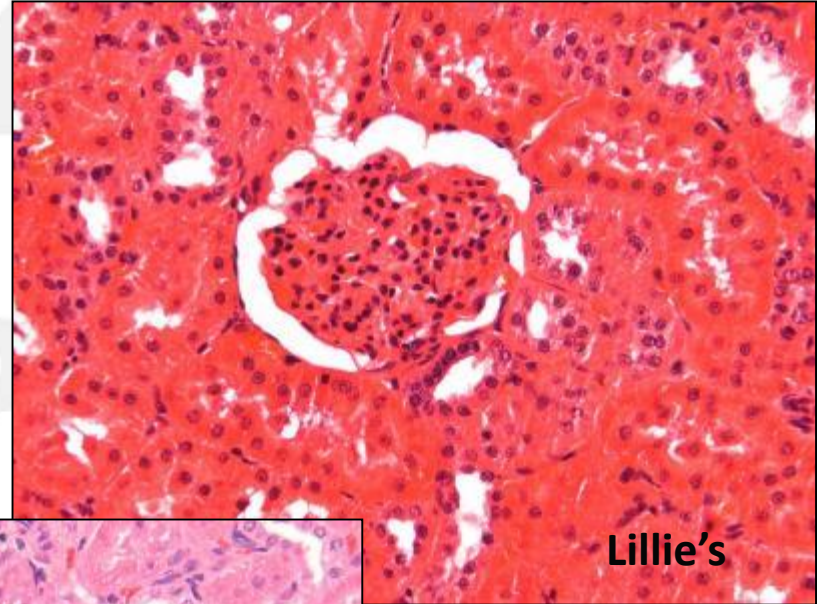
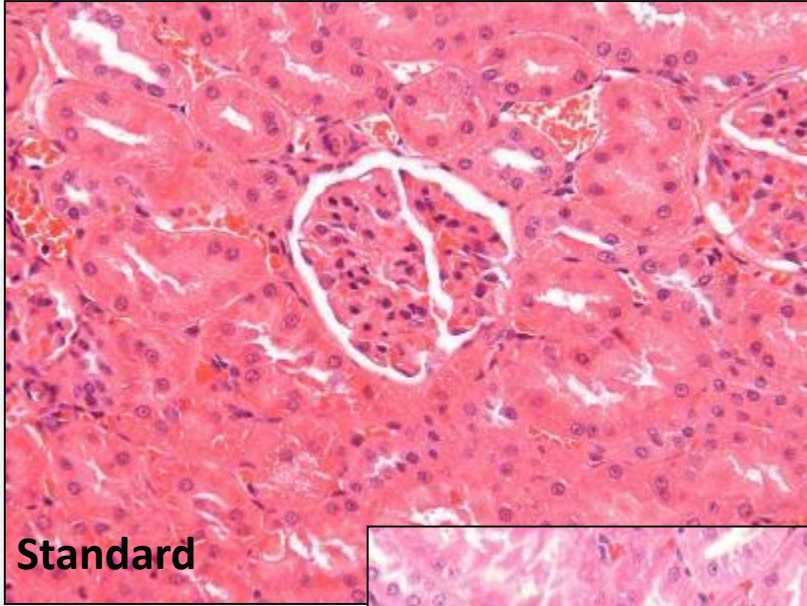
Postmortem hepatocellular cytoplasmic vacuolation



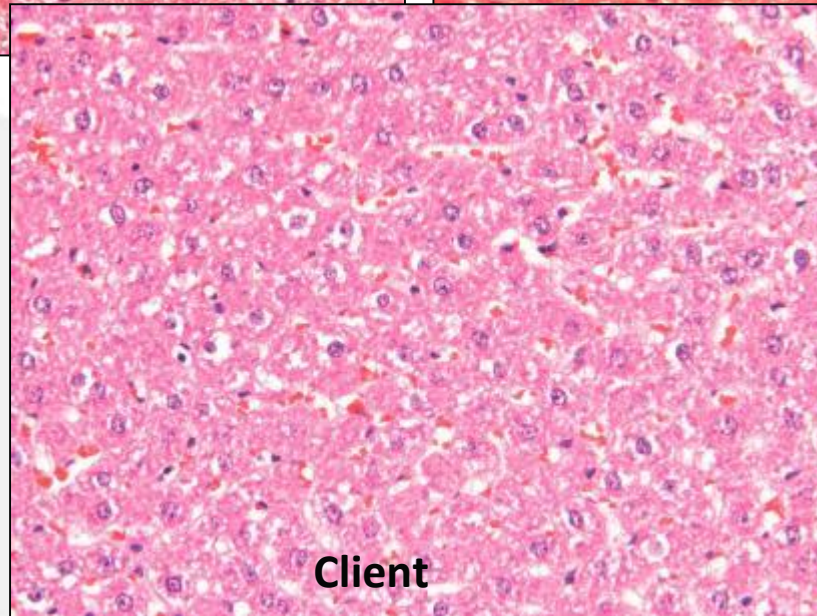
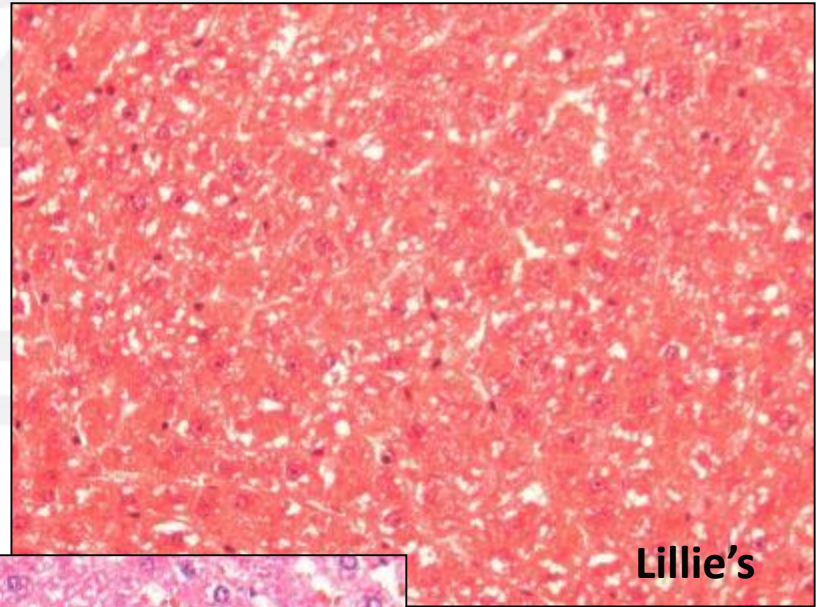
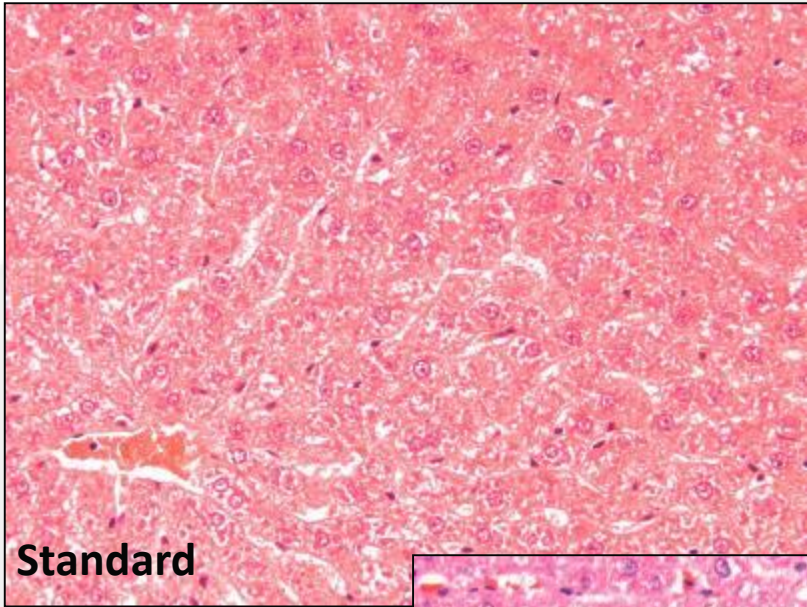
Staining

- routine staining may reveal different appearance of structures **EVEN** by hematoxylin&eosin
- personal experience and training
- special stains and immunohistochemistry may cause confusion if:
 - tissues under examination that are rarely being evaluated
 - false negative or positive immune reactivity

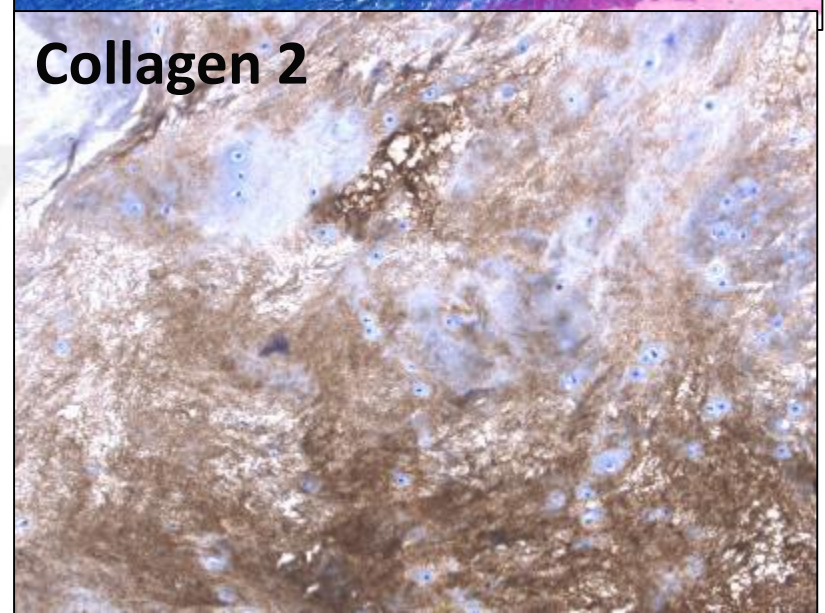

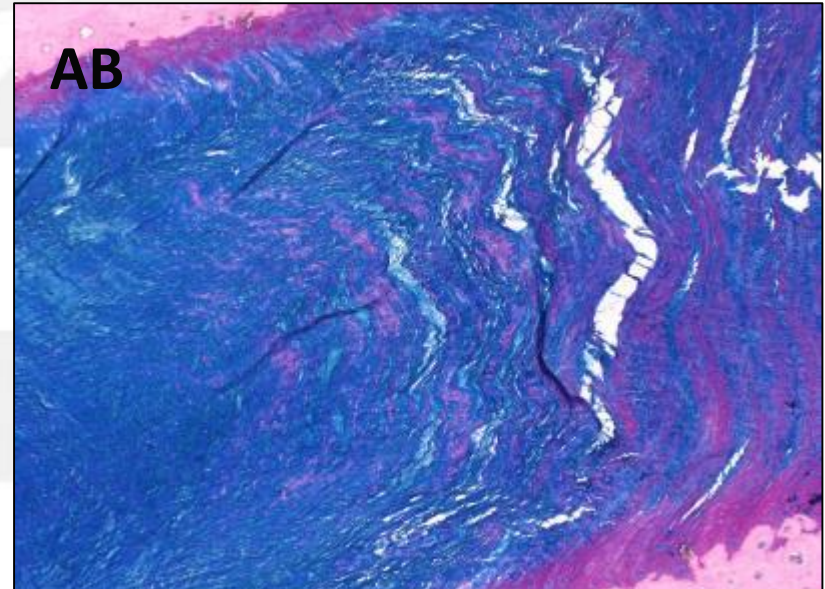
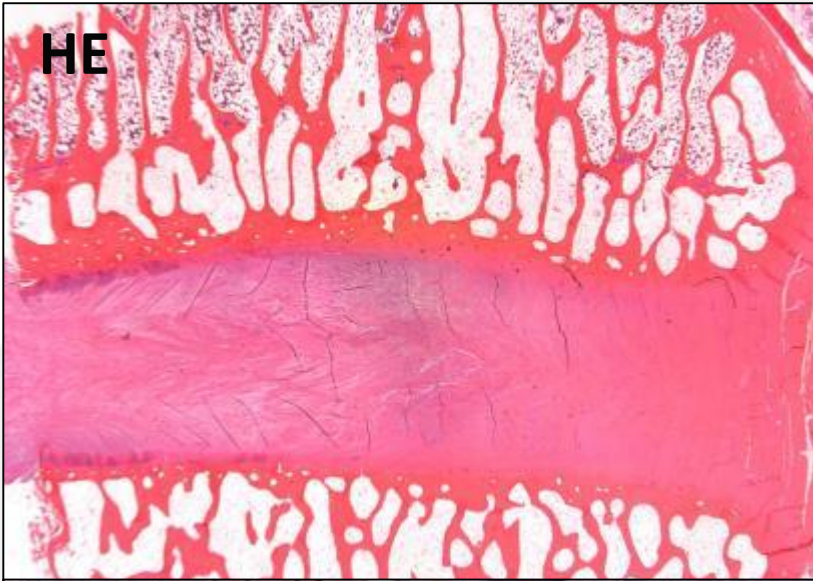
Different H&E Staining: Kidney



Different H&E Staining: Liver



Rarely evaluated tissues: e.g. Sheep-intervetrebrel discs



What about experience?

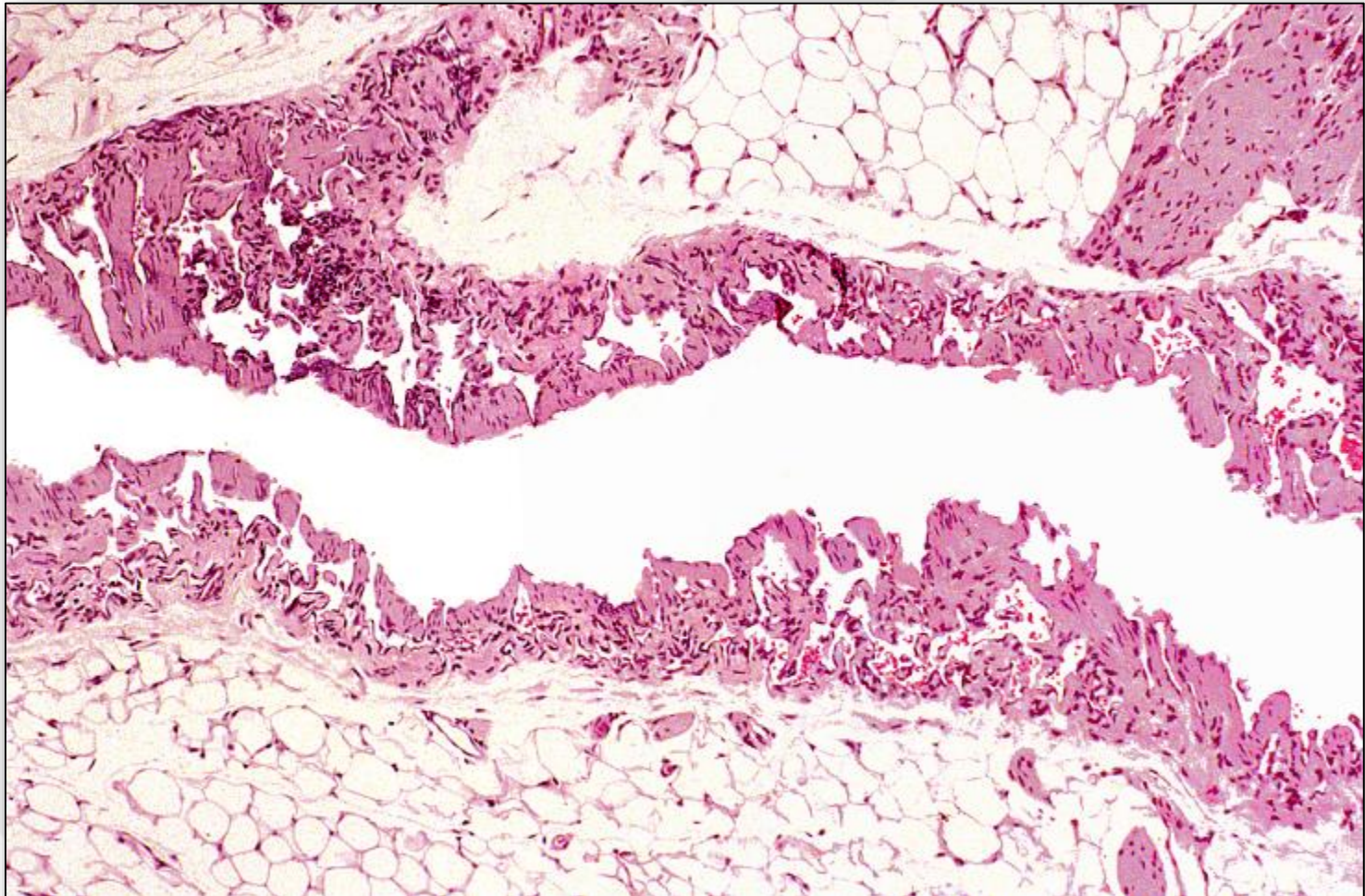
- rare or unusual lesions may be unknown to the pathologist
- over many years there was a lack in case publications
- PR should be applied to each study

**,Reading an oncogenicity study is sooo difficult....!
Is this true?**

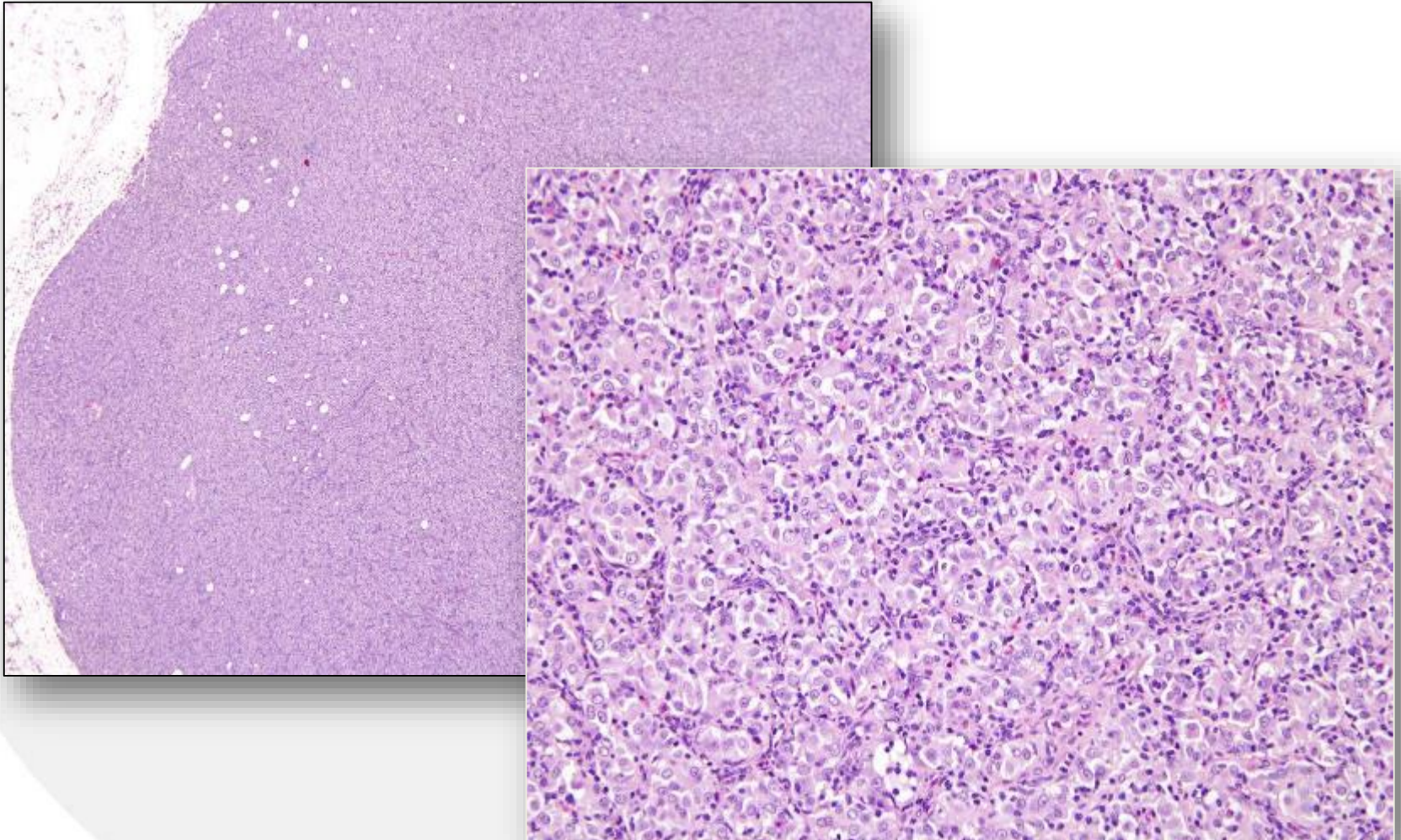
- Short term vs long term studies

Rare or unusual findings

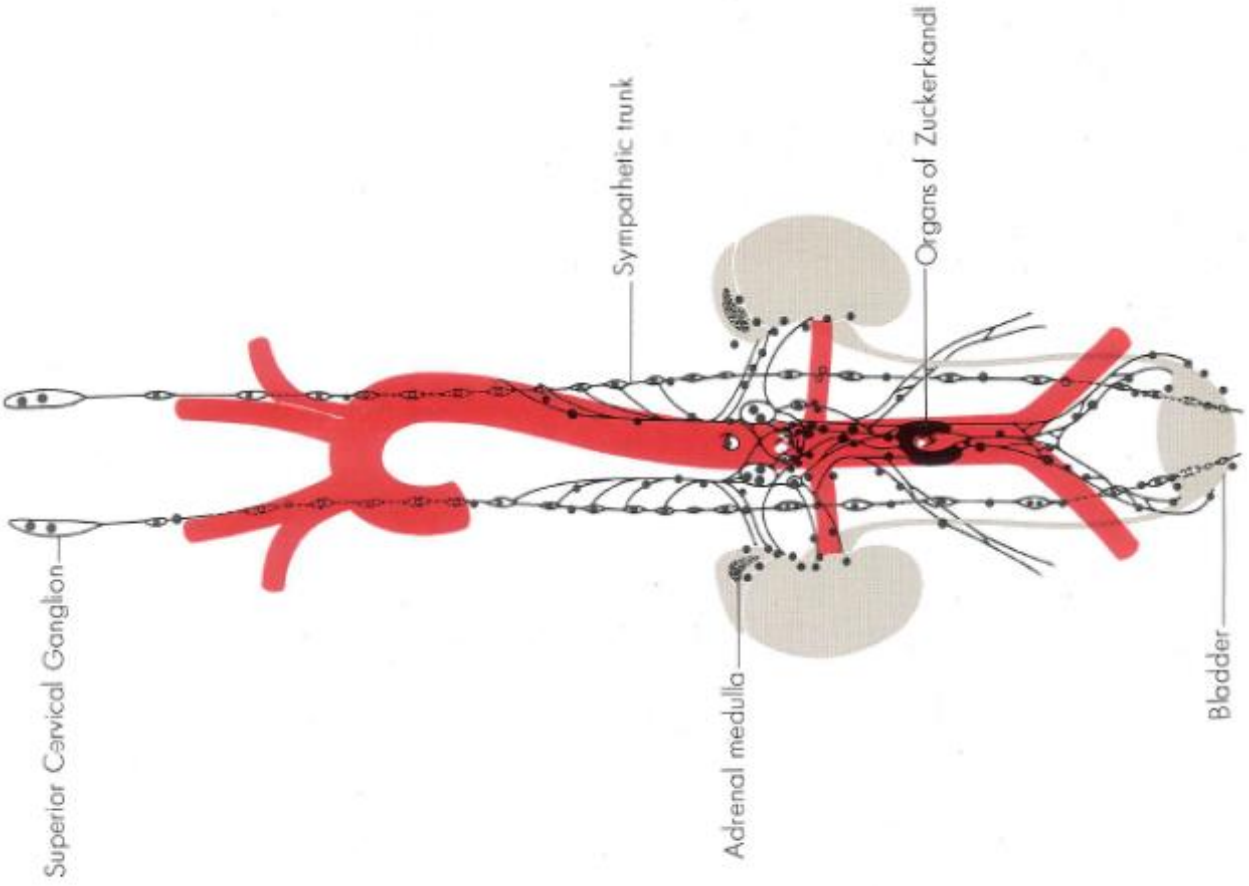
Mesenteric Vein - Plexiform Vasculopathy



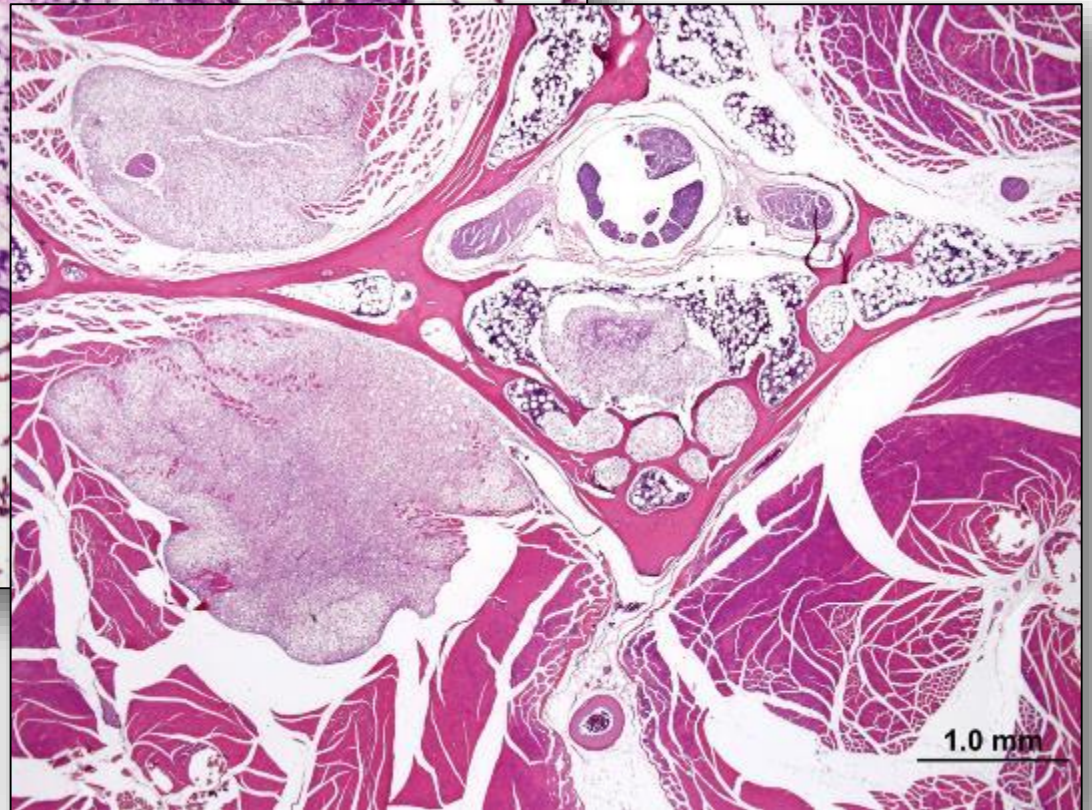
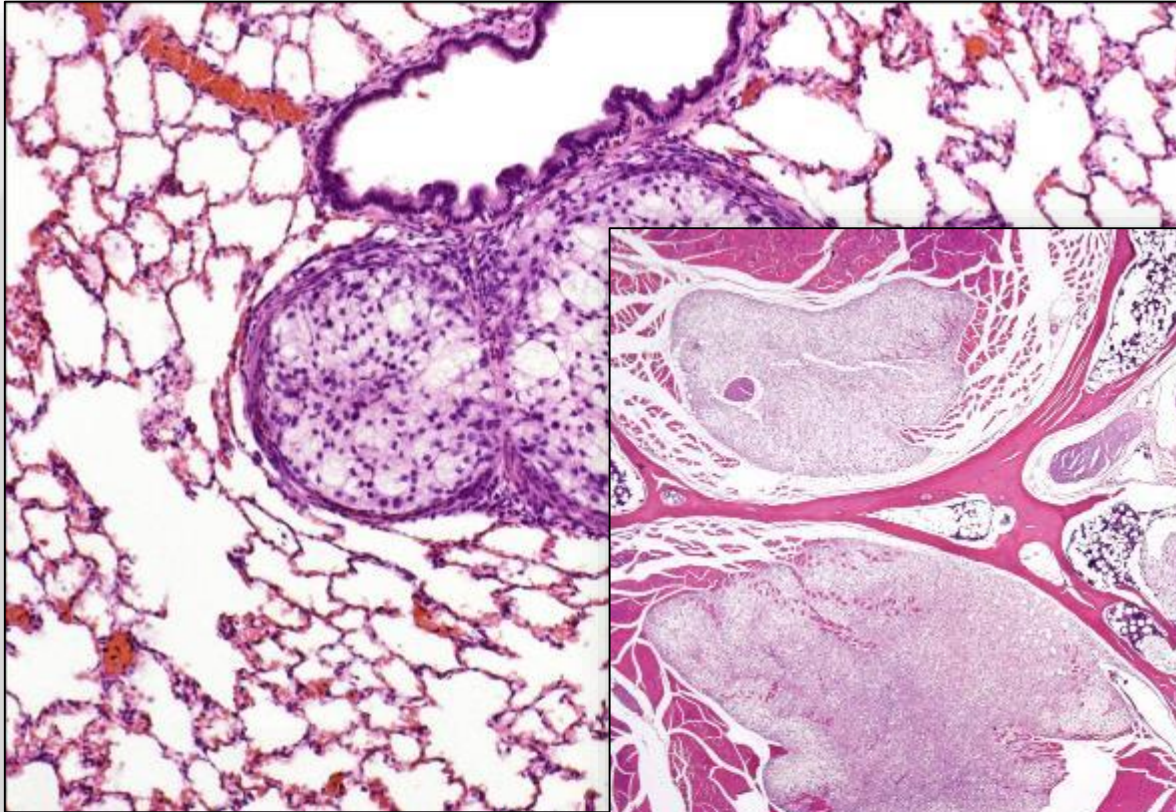
Organ of Zuckerkandl (periaortic paraganglioma)



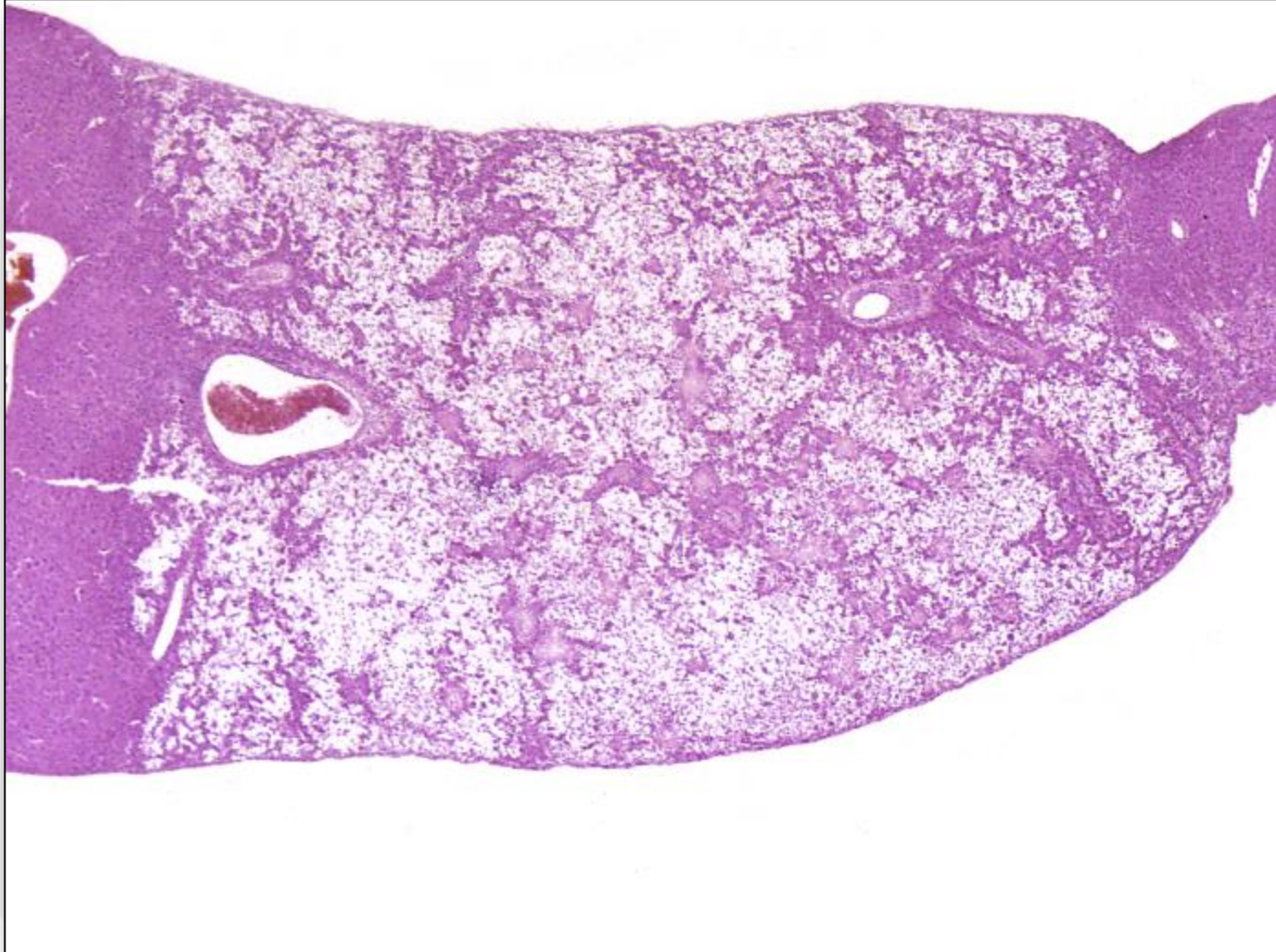Organ of Zuckerkindl (periaortic paraganglioma)



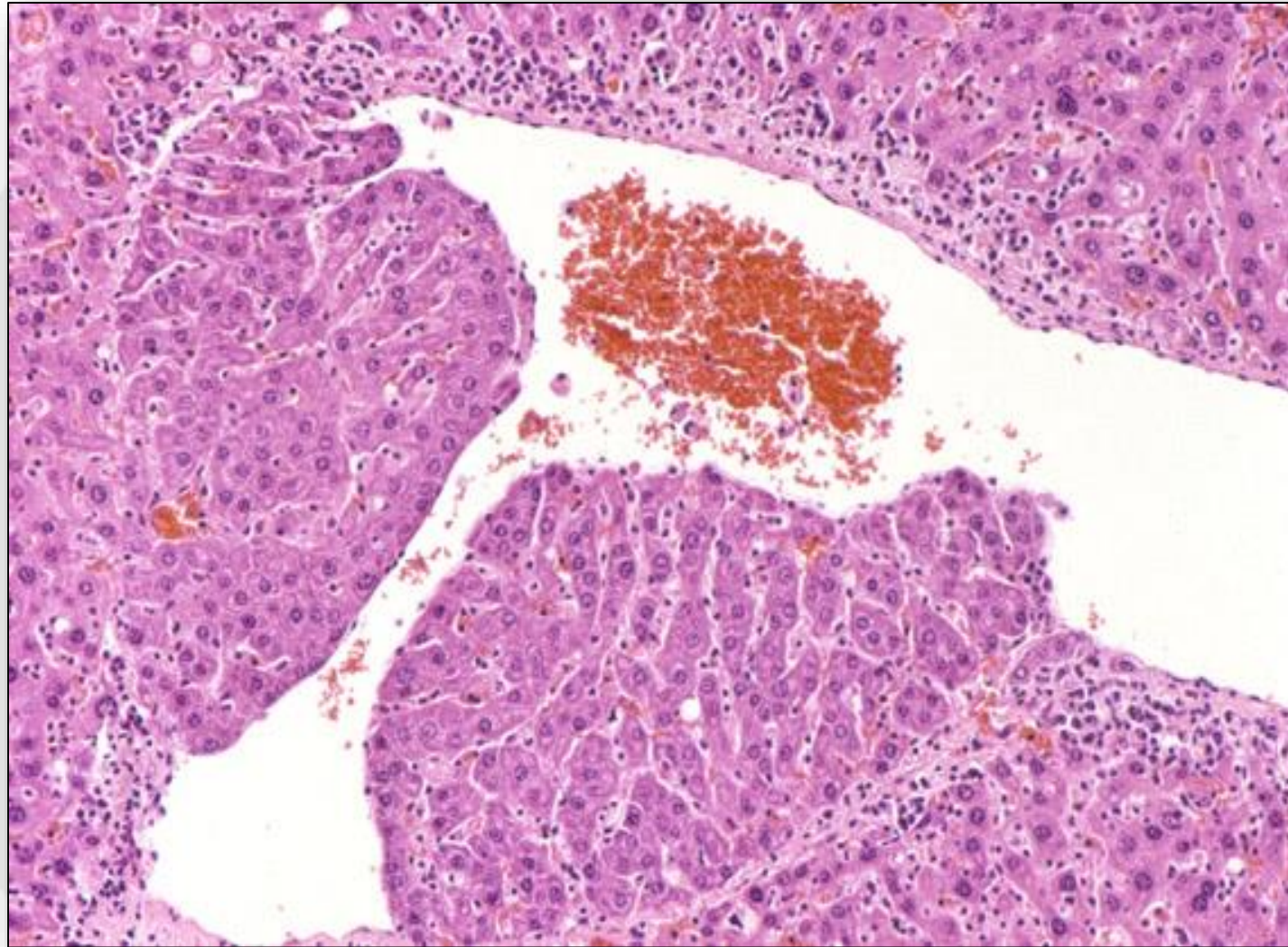
Perivertebral chordoma metastatic to lung



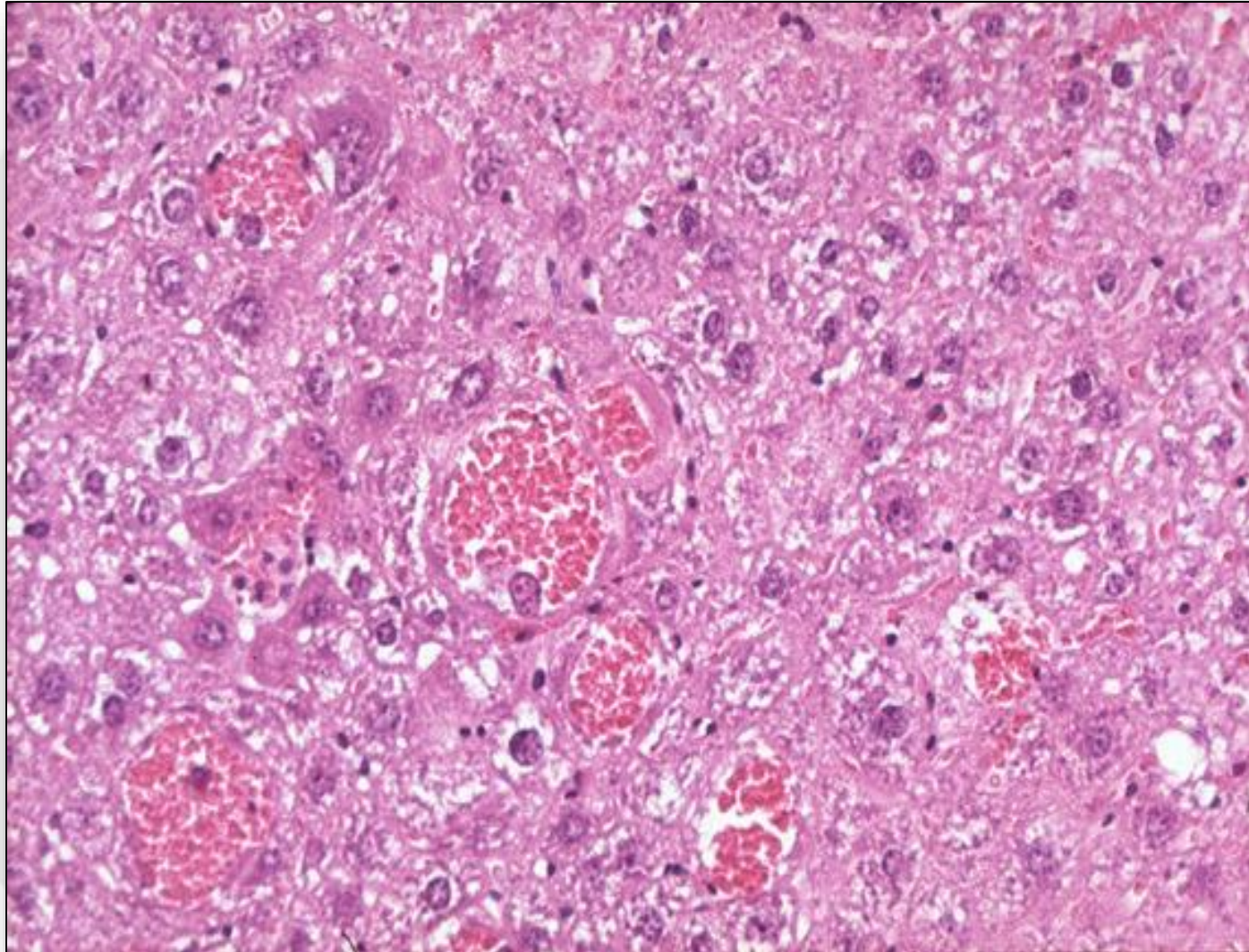
Ito-tumor in mouse liver



Mouse liver – Intravascular hepatocytes



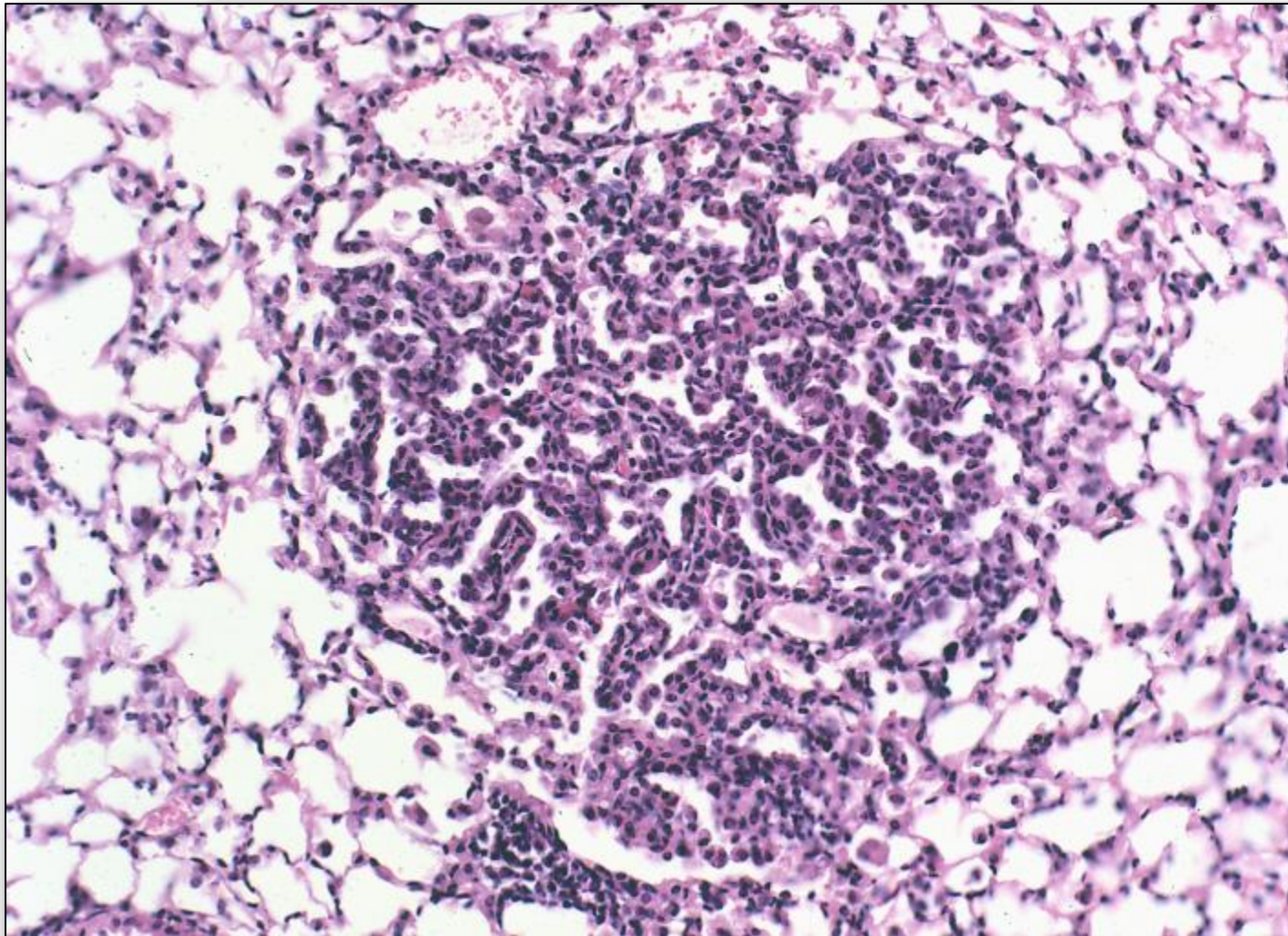
Mouse liver – Intrahepatocytic erythrocytes



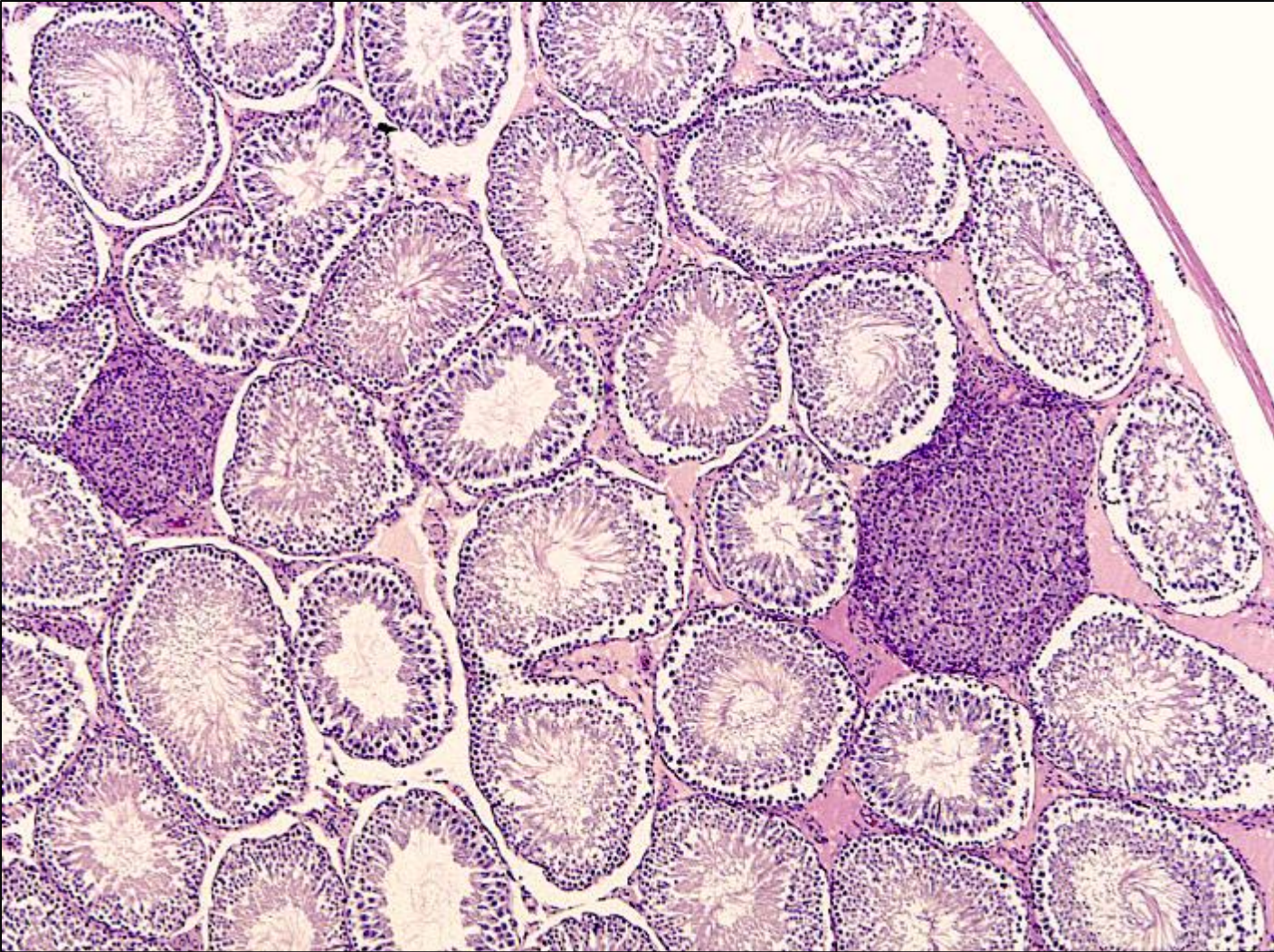
Misdiagnosis

- **Threshold for diagnosis of lesion (especially non-neoplastic aging lesions)**
- **Use of different terminology for same lesions within one study**
- **Wrongly used terminology**

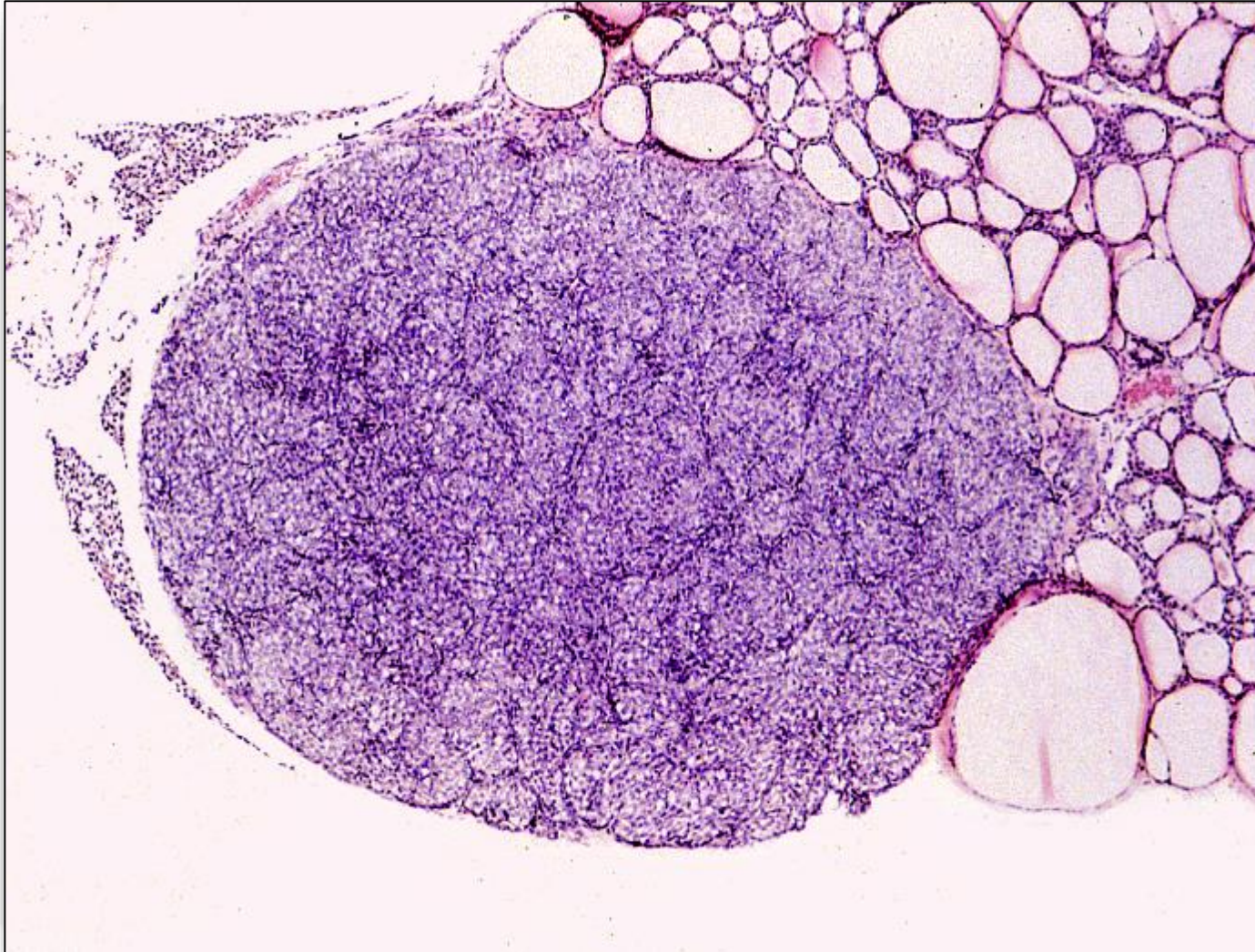
Alveolo-bronchiolar hyperplasia vs Adenoma



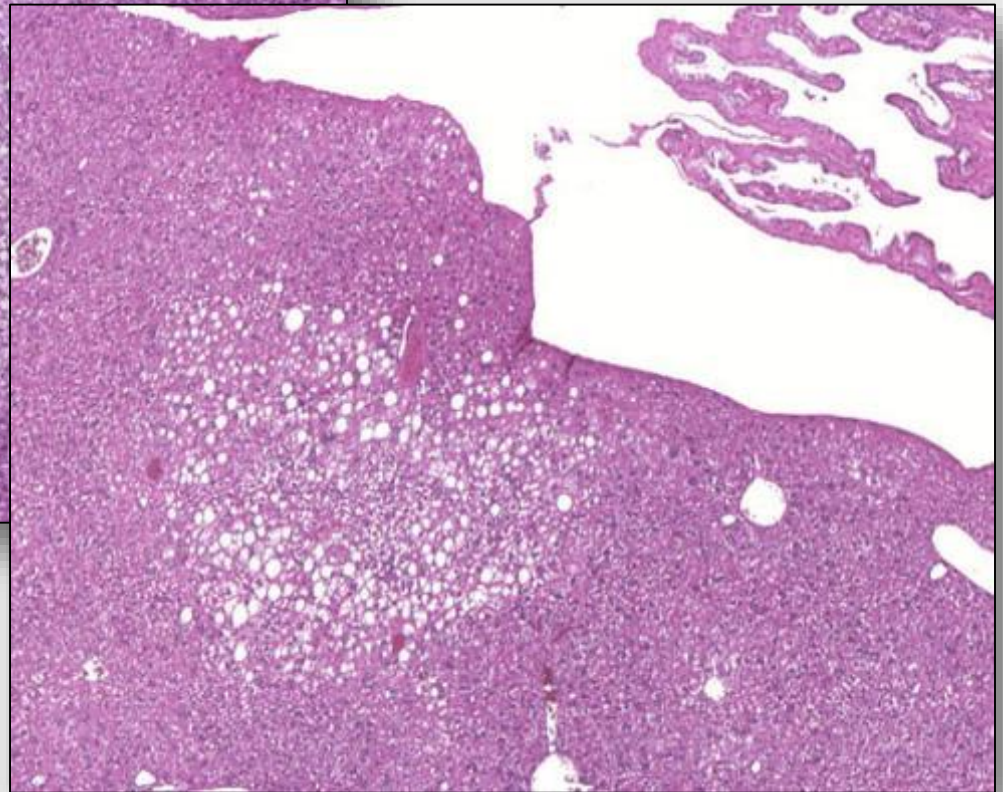
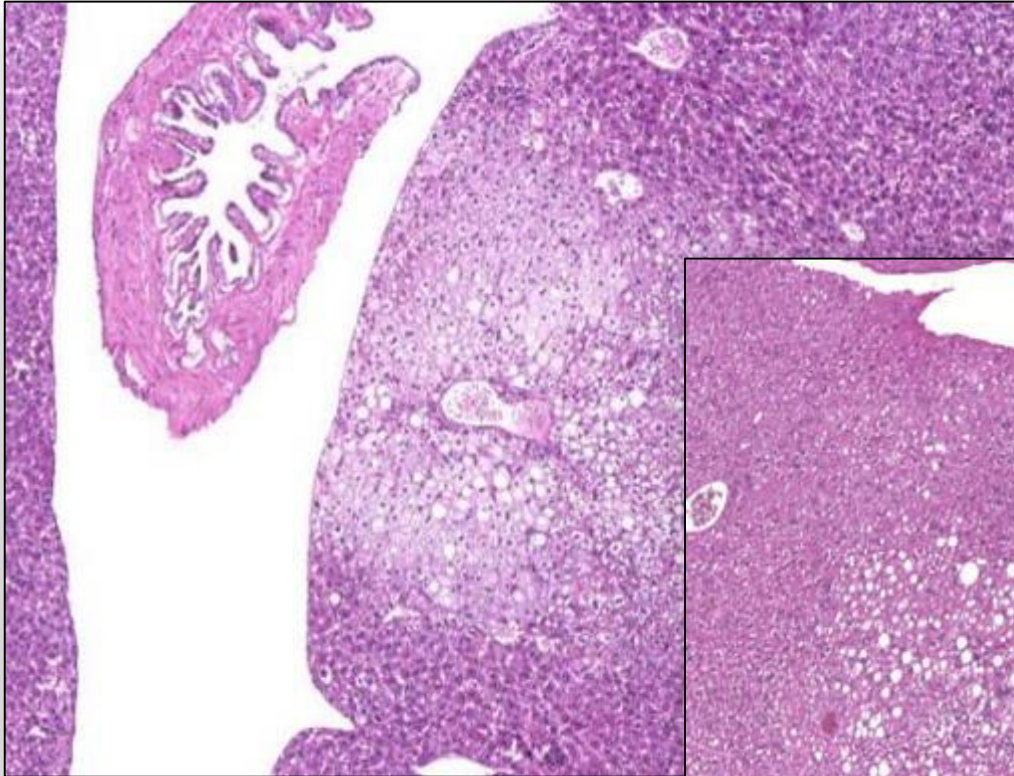
Leydig cell hyperplasia vs adenoma



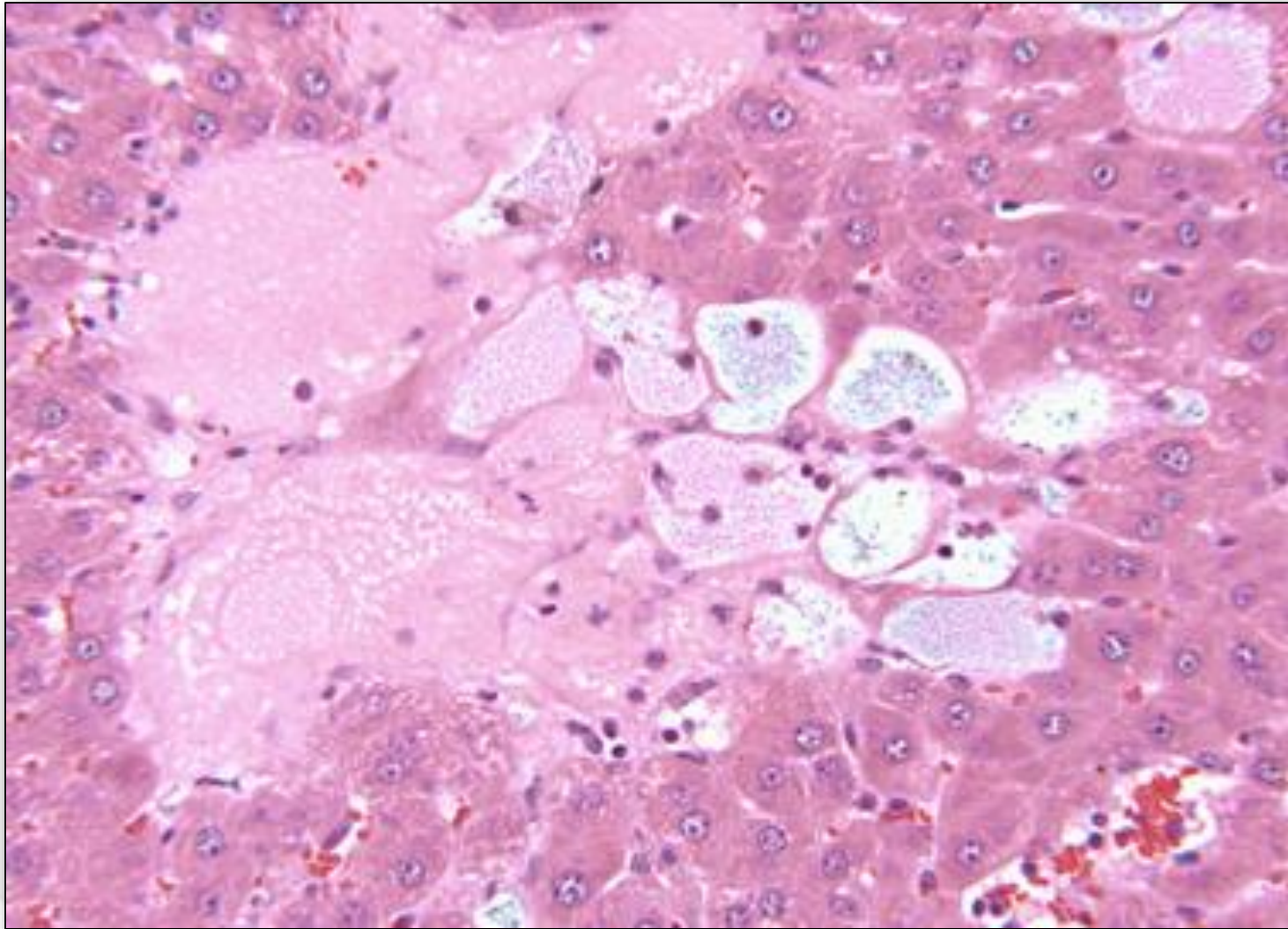
Parathyroid gland hyperplasia vs adenoma



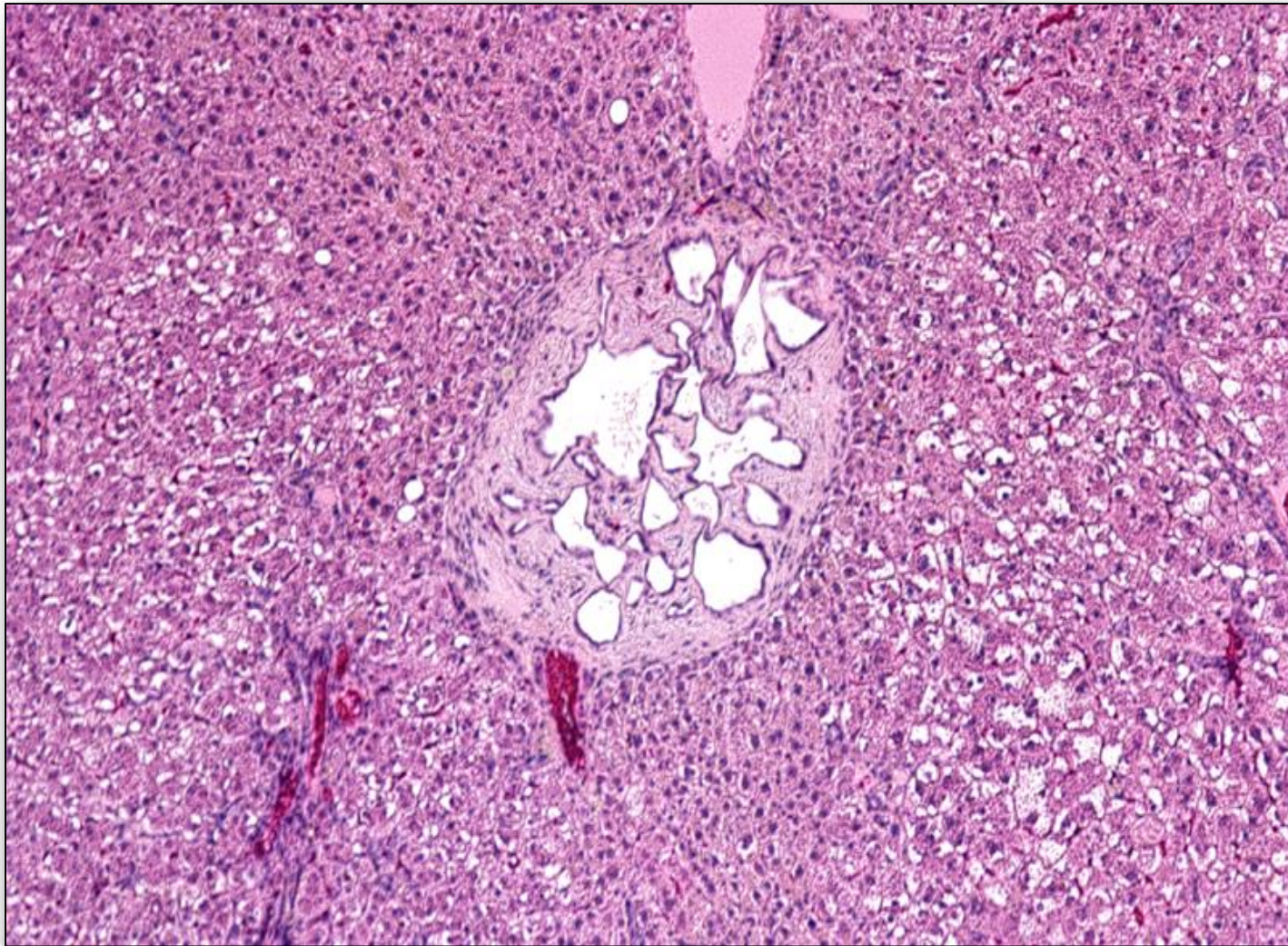
Tension lipidosis



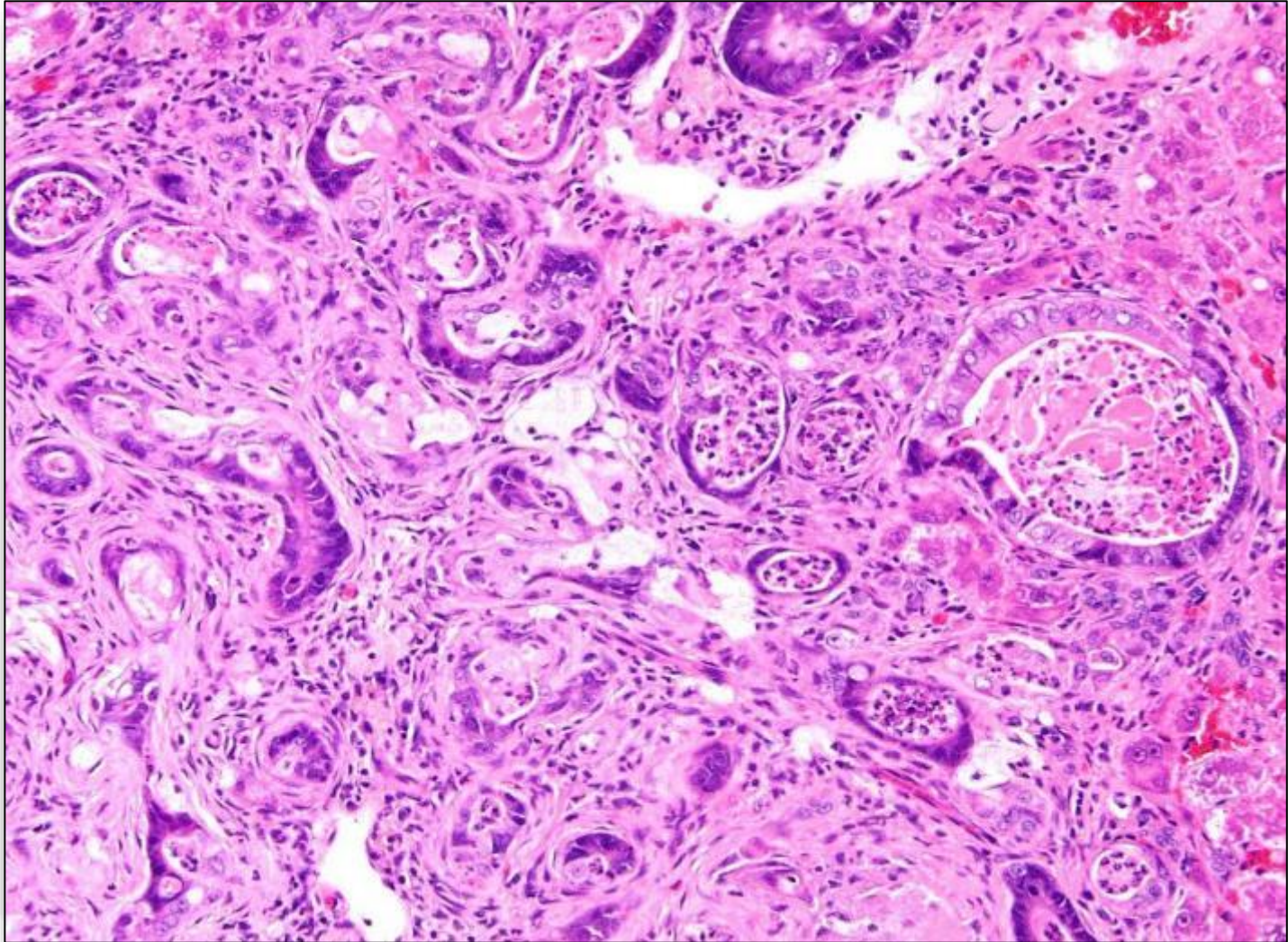
Spongiosis hepatis or Cystic degeneration



Peribiliar fibrosis vs cholangiofibrosis



Cholangiofibrosis

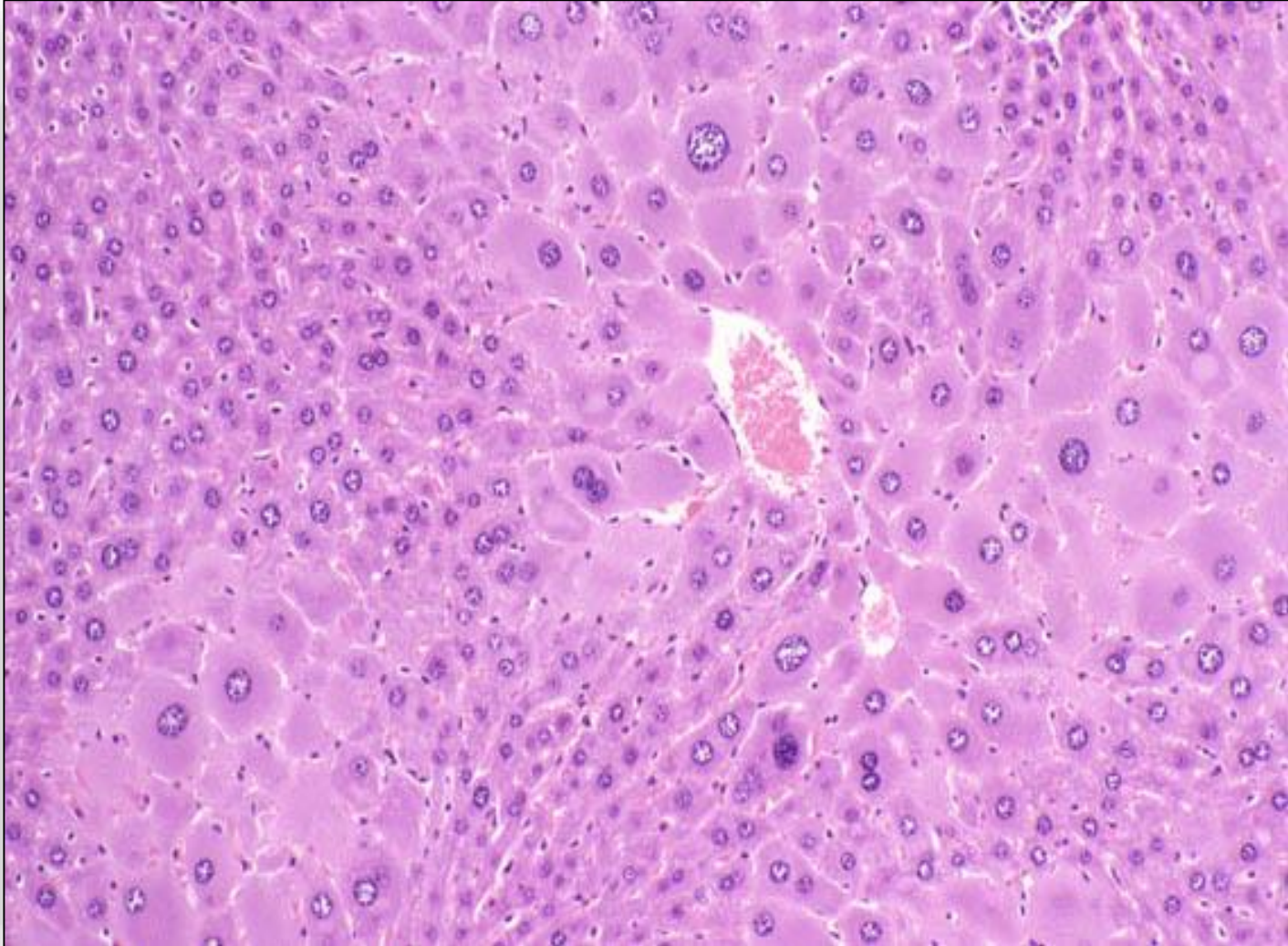


Pharmacologic effects rather than Pathological lesions

- **The inappropriate interpretation of pharmacological effects may cause in wrong settings of the NOAEL**
- **Adverse:**
changes that are irreversible and not foreseen, i.e. irreversible changes on cells, tissues, organs or individuals
- **Adverse effects include:**
degeneration, necrosis, apoptosis, fibrosis, architectural changes etc.

Pharmacological effects:

Examples - Hepatocellular hypertrophy, mouse

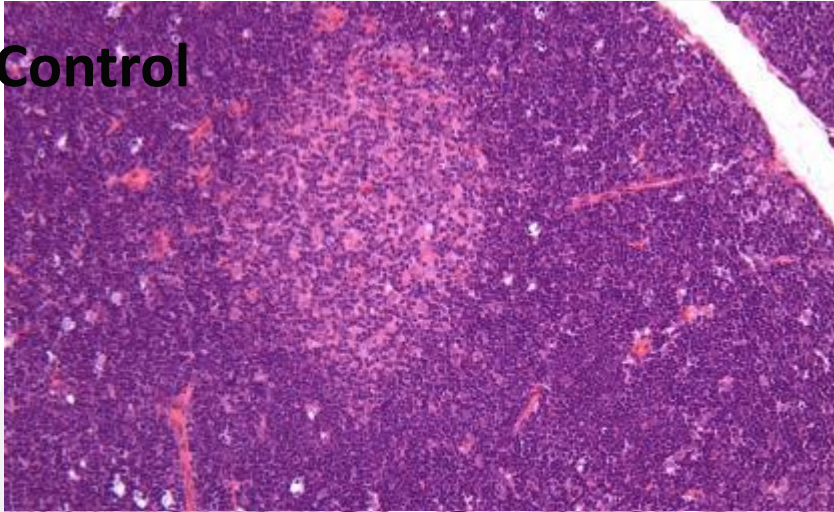


Pharmacologic effects may be proven by mechanistics

- **Non-adverse effects are reversible**
- **Architectural changes may be confusing but need to be reversible**
- **Human relevance need to be investigated for several lesions especially when considered to be due to endocrine affections**

Pharmacologic effects: Example - low dose corticosteroids, rats

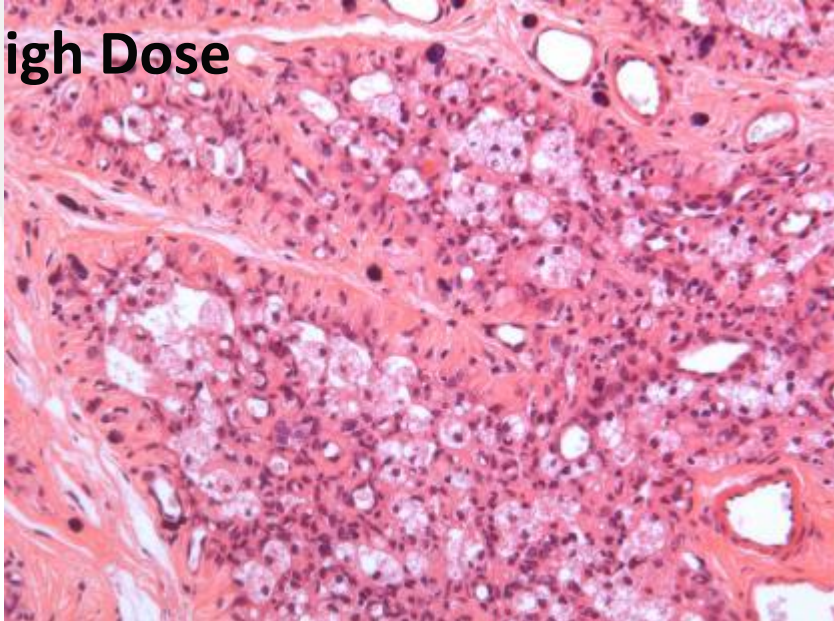
Control



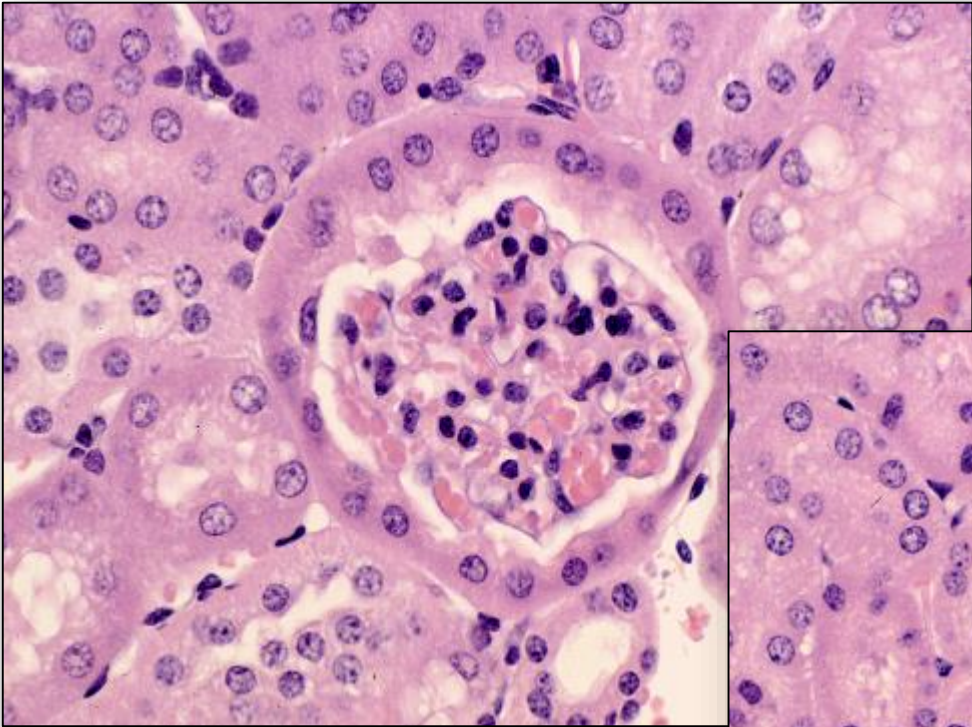
Cortical and medullary atrophy
Increased histiocytosis
Lymphocytolysis
Lymphocytophagocytosis

Full Recovery after 14 days!

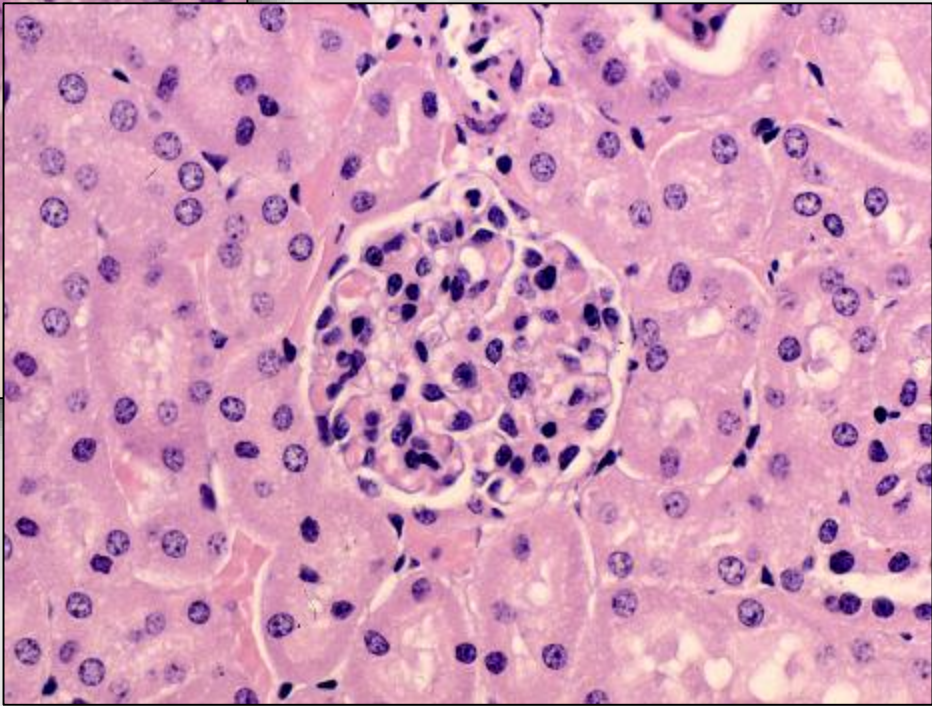
High Dose



Sexual dimorphism



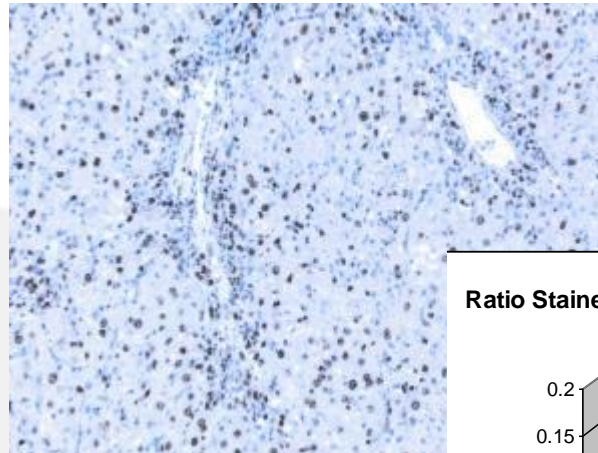
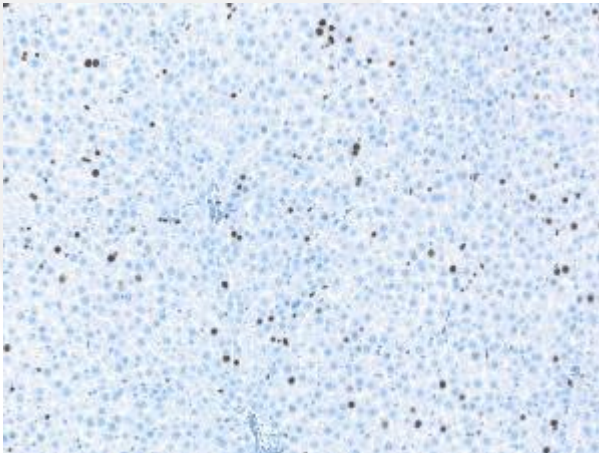
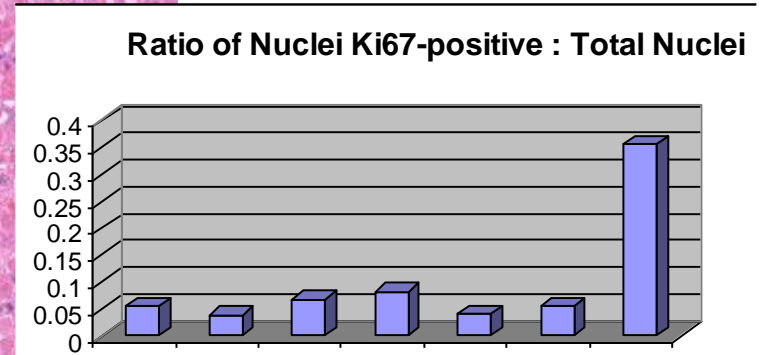
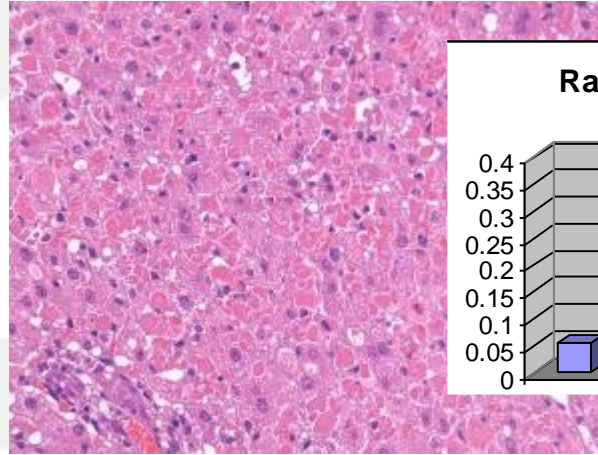
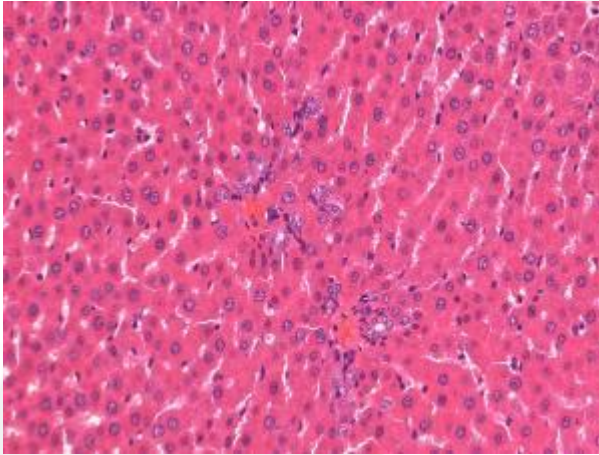
**Control Female
Mouse
Renal Glomerulus**



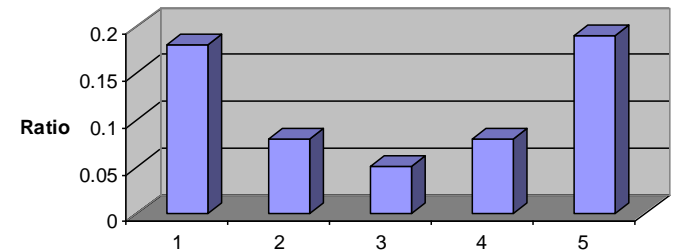
**Control Male
Mouse
Renal Glomerulus**

Pharmacologic effects may be proven by mechanistics

Example: FXR agonist rat



Ratio Stained Multinucleated vs Stained Hepatocytes of Groups B1-B5



Summary

- **All sections are artifacts**
 - **All sections have additionally introduced artifacts**
 - **Some artifacts are avoidable**
 - **Considering correct fixation prior to necropsy**
 - **Clear-cut techniques**
 - **Quality check on sections**
-
- **Interpretation and Errors**
 - **PR and PWG**
 - **Adverse vs Non-adverse**
 - **Relevance for Human**